

Original Article**Sex Determination from Sacrum and Coccyx measurements using Magnetic Resonance Imaging in a sample of Egyptian Population**

Shereen Ahmed Elkhateeb¹, Marwa Elsayed Abd Elhamed², Mona Sami Hamed³, Marwa AbdEl-Moniem Amer¹

¹Departments of Forensic Medicine and Clinical Toxicology, ²Radio diagnosis, ³Community Medicine and Public Health, Faculty of Medicine, Zagazig University, Egypt

ABSTRACT

Corresponding author:

Shereen Ahmed
Elkhateeb

Sheren_elkhateeb2001
@yahoo.com

Background: Estimation of sex is an important item in identification of unidentified persons. The aim of the current work was to evaluate sacrum and coccyx gender differences using magnetic resonance imaging (MRI) in Egyptian population.

Subjects and method: 230 Egyptian subjects (115 males and 115 females) were investigated with MRI over the sacrum and coccyx. MRI images of every person were used to get seven length estimations and two angle dimensions in the sacrum and coccyx.

Results: Measured lengths including anterior sacral length (ASL), posterior sacral length (PSL), anterior sacrococcygeal length (ASCL), posterior sacrococcygeal length (PSCL) and antero-posterior diameter of S1 vertebra corpus (APD) were higher in males. But there was no significant variation in maximum breadth of alae sacralis (MBA), maximum lumbo-sacral curve angle (MLSCA) and lumbo-sacral angle (LSA) between males and females. Univariate discriminant function analysis showed that ASL

and PSL recorded 71.9% and 71.5% accuracy rates respectively. Stepwise analysis considered that (ASL and PSL) collectively produced 68.9% correct prediction rate.

Conclusion: the results of the current work concluded that the sacrum and coccyx are valuable for gender differentiation, can be helpful for sex identification of skeletal remnants in the Egyptian when utilized with other methods as assessment of other readily accessible bones.

Keywords: Forensic anthropology; Magnetic resonance imaging; Sacrum and coccyx; Egyptian; Discriminant function analysis.

I. INTRODUCTION

A crucial step toward making a successful identification in forensic medicine is to establish a biological profile that includes gender, age, ethnicity and stature (Benazzi et al., 2009). However, sex

determination in fragmented, mutilated or putrefied bodies represents a significant aspect of forensic investigation (Akhlaghi et al., 2016). It is known that morphological and anthropometric techniques are used to examine skeletal remains for this purpose

(Novak, 2016). Researchers have explored the use of statistical analyses and set up sex assessment equations using different bones like the sternum, scapula, patella, metacarpals and phalanges (Franklin et al., 2012; El Morsi and Al Hawary. 2013; Torimitsu et al., 2016 and Yasar et al., 2018).

The functions of pelvic bones differ in both sexes where these bones are adapted to permit easy delivery process in females. So, sacrum and coccyx are valued bones in sex prediction (Mamatha et al., 2012). The sacrum and coccyx measurements were evaluated by some researchers (Plochocki, 2011, Torimitsu et al., 2017 and Zhan et al., 2018). Populations differ in their skeletal development due to genetic and environmental components, which affect morphological and metric assessments of biological profiles. So, special equations are needed for each population to enhance accuracy of identity (Ross et al., 2011 and Torimitsu et al., 2017).

Magnetic resonance imaging technique offers a way to examine all types of tissue with relatively low radiation effects (Yasar et al., 2018). So, the aim of the current work was to evaluate sexual difference of sacrum and coccyx using MRI image-based morphometric data to set up a discriminant equation for sex assessment in Egyptian population.

II. SUBJECTS AND METHOD

This comparative Cross-sectional study was performed in Mit Ghamr Oncology Center, Dakahlya governorate, Egypt and approved from the ethics committee of Zagazig University (ZU-IRB#6436). Written

informed consent was given by all individuals.

2.1 Subjects:

This study included 230 Egyptian subjects (115 males and 115 females). The male ages ranged from 18-77 years old and female ages ranged from 27- 60 years old. Inclusion criteria included Egyptian population of both sex with age ≥ 18 years. Exclusion criteria included age < 18 years, Patients that not allowed to do MRI as those with cardiac pacemaker and cochlear implant. Patients with fractures or any surgical operation that would modify the dimensions of the sacrum and coccyx. We excluded also patients with history of congenital developmental dysplasia, metabolic bone diseases, tumors and osteoarthritis in the region of the sacrum and coccyx.

2.2 Method:

Magnetic resonance imaging scans was obtained in Mit Ghamr Oncology Center with 1.5 Tesla machine (Siemens, aera). The Research comprised of four spin echo sequences; a coronal localizer with repetition time and echo time (TR/TE) of 400/15 msec, a sagittal view with a TR/TE of 300-600/11-23 msec, an axial view with a TR/TE of 700-900/11-15 msec, and a sagittal view with TR/TE (dual- echo sequences) of 2500-2600/16-21 & 90-105 msc. Seven length measurements and two angles were performed as reported by (Torimitsu et al., 2017; Zhan et al., 2018; Etili et al., 2019). They are summarized in (Table 1, Figure 1, 2).

2.3 Statistical analysis

All statistical analyses were done using SPSS version 22.0 computer software

(IBM, Armonk, NY, USA). The Shapiro-Wilk test and Levene's test were done to estimate normality and equality of variables. Student's-t-test was used for comparison of means between 2 sexes. A p-value < 0.05 was rated significant and p-value > 0.05 was rated non-significant. A univariate discriminant function analysis

(DFA) was done for every measurement to deduce an equation for gender identity. A stepwise DFA to deduce a formula for the most accurate sex classifications. Wilk's lambda values were done to evaluate to what extent each equation classified the examined samples into males and females.

Table 1: Sacral and coccygeal parameters

Parameter	Description	Image
Anterior sacral length (ASL)	Linear distance from the anterosuperior edge of first sacral vertebra (S1) to the anteroinferior edge of Fifth sacral vertebra (S5).	Sagittal
Posterior sacral length (PSL)	Linear distance from the posterosuperior edge of S1 to the anteroinferior edge of S5.	Sagittal
Anterior sacrococcygeal length (ASCL)	Linear distance from the anterosuperior edge of S1 to the anteroinferior edge of Last coccygeal vertebra (LCV).	Sagittal
Posterior sacrococcygeal length (PSCL)	Linear distance from the posterosuperior edge of S1 to the anteroinferior edge of the LCV.	Sagittal
Maximum Breadth of Alae Sacralis (MBA)	Maximum transverse distance between the two most lateral parts of the sacral alae.	Axial
Maximum Antero-Posterior Diameter of S1 Vertebra Corpus (APD)	Linear distance from the two anterior point to the most posterior point on the body of S1.	Axial
Maximum Transverse Diameter of S1 Vertebra Corpus (MTD)	Linear distance between the two most laterally projecting points on the body of S1.	Axial
Lumbo-Sacral Angle (LSA)	the angle formed between the long axis of the lumbar vertebrae and the sacrum.	Sagittal
Maximum Lumbo-Sacral Curve Angle (MLSCA)	the widest angle among the angles of intersecting sacral and lumbar vertebrae corpus lines was proposed.	Sagittal

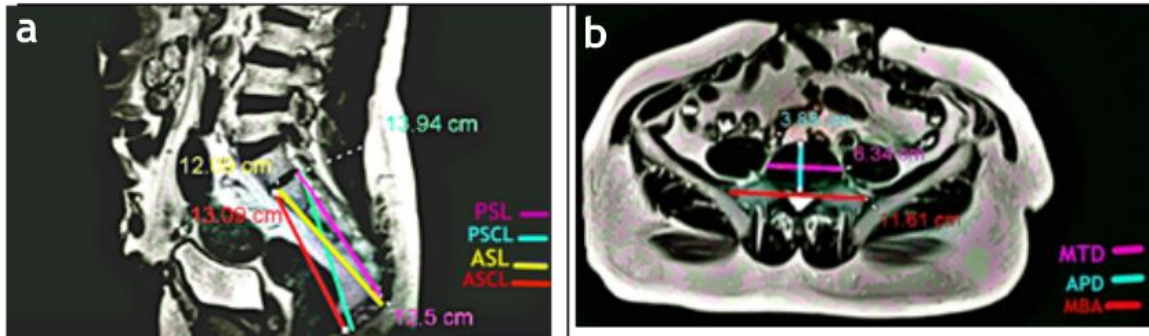


Figure 1: MRI image showing (a): measurements of posterior sacral length (PSL), posterior sacrococcygeal length (PSCL), anterior sacral length (ASL), anterior sacrococcygeal length (ASCL) in the sagittal plane; (b): antero-posterior diameter of S1 vertebra corpus (APD), maximum transverse diameter of S1 vertebra corpus (MTD) and maximum breadth of alae sacralis (MBA) in the axial plane.

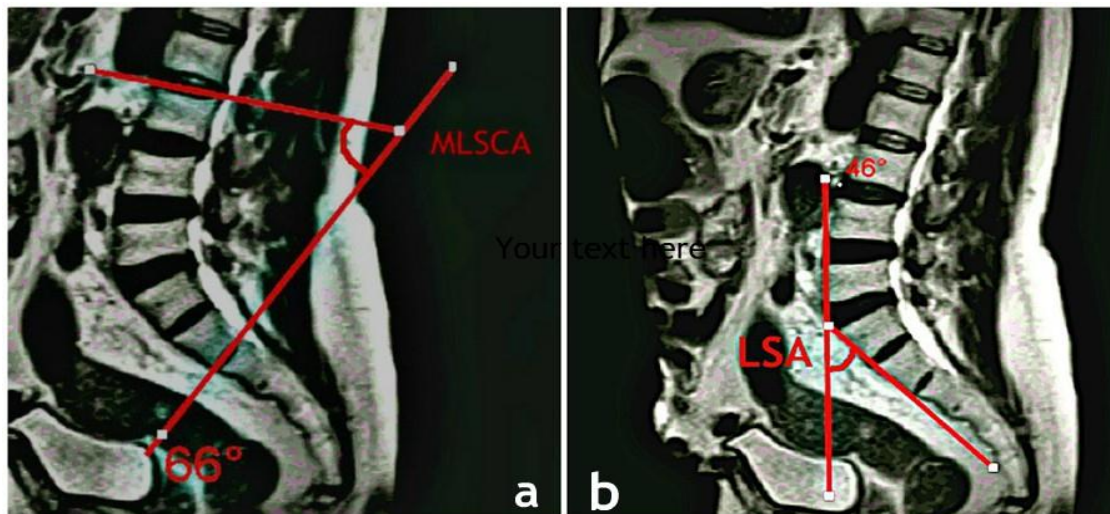


Figure 2: MRI image showing (a): maximum lumbo-sacral curve angle (MLSCA); (b): lumbo-sacral angle (LSA) in the sagittal plane.

III. RESULTS

The mean values of anterior sacral length (ASL), posterior sacral length (PSL), anterior sacrococcygeal length (ASCL), posterior sacrococcygeal length (PSCL) and antero-posterior diameter of the first sacral vertebra corpus (APD) showed significant higher values in males ($p < 0.001$). However, no significant variation

was observed in the mean values of MTD, MBA, LSA and MLSCA between both sexes ($p > 0.05$) (table 2).

Posterior sacral length (PSL), (PSCL) and (ASL) producing high value F's (Tests of Equality) provides strong statistical evidence of significant difference between means of males and females for

all independent variables (table 3). Through univariate discriminant function analysis, ASL showed most significant measurements to sex identification, then, PSL that showed 71.9% and 71.5% of accuracy respectively (table 4).

Stepwise analysis of all measurements of the sacrum and coccyx showed that (PSL and ASL) gave 68.9% correct prediction rate (table 5).

Table 2: Comparison of sacrum and coccyx measurements in both sexes by Student's t-test.

Parameters	Male (n= 115)				Female (n=115)				Student t-test	P-value
	Mean	SD.	Min.	Max.	Mean	SD.	Min.	Max.		
Age (years)	46.37	19.3	18	77	42.05	9.4	27	60	2.146	0.034*
ASL (cm)	10.9	1.01	8.6	12.33	10.03	1.11	7.5	12.01	6.25	0.000*
PSL (cm)	11.09	0.91	9.2	12.5	9.8	1.24	7.3	12.19	8.85	0.000*
ASCL (cm)	12.63	1.34	9.9	14.98	11.96	1.09	9.5	13.74	4.16	0.000*
PSCL (cm)	13.5	1.41	10.9	16.54	12.2	1.18	9.7	14.48	7.20	0.000*
APD (cm)	3.8	0.40	3.3	4.9	3.5	0.41	2.9	4.28	4.03	0.000*
MTD (cm)	5.7	0.78	4.7	7.9	5.59	0.55	4.6	6.75	1.42	0.155
MBA (cm)	11.4	0.9	10.5	13.4	11.29	0.88	8.9	13.61	1.29	0.197
LSA (degree)	48.7	8.11	3	68	47.0	9.1	29	66	0.97	0.329
MLSCA (degree)	70.56	7.85	58	88	69.4	9.12	51	85.0	1.03	0.304

n: number of cases; SD: standard deviation; Min: minimum; Max; maximum; cm: centimeter; *significant at $p < 0.05$

Table (3): Tests of Equality of Group Means

Parameters	Wilks' Lambda	F	p-value
Age (years)	.980	4.590	.033
ASL (cm)	.852	39.142	.000*
PSL (cm)	.742	78.435	.000*
ASCL (cm)	.929	17.351	.000*
PSCL (cm)	.813	51.879	.000*
APD (cm)	.933	16.281	.000*

cm: centimeter; *significant at $p < 0.05$

Table 4: Direct discriminant function analysis.

Parameters	unstandardized coefficient	Group centroid		Wilk's lambda	Correct prediction rate (%)		
		Male	Female		Male	female	overall
Age (years) constant	0.066 -2.907	0.142	-0.142	0.980	47.4	69.3	58.3
ASL (cm) Constant	0.937 -9.819	0.414	-0.414	0.852	78.1	65.8	71.9
PSL (cm) Constant	0.913 -9.541	0.587	-0.587	0.742	77.2	65.8	71.5
ASCL (cm) Constant	0.815 -10.029	0.276	-0.276	0.929	71.9	65.8	68.9
PSCL (cm) Constant	.766 -9.870	0.477	-0.477	0.813	65.8	71.1	68.4
APD (cm) Constant	2.463 -9.111	0.267	-0.267	0.933	56.1	56.1	56.1

cm: centimeter

Table 5: Stepwise discriminant function analysis.

Measurements	unstandardized coefficient	Function	Group centroid		Wilk's lambda	Correct prediction rate (%)		
			Male	Female		Male	female	overall
PSL (cm)	1.397	0.945	0.62	-0.62	0.720 **	76.3%	61.4%	68.9%
ASL (cm)	-.628	0.668						
ASCL (cm)	---	0.660						
PSCL (cm)	---	0.540						
APD (cm)	---	0.471						
age (years)	----	0.232						
Constant	-8.028							

cm: centimeter; ** highly significant Wilk's lambda

IV. DISCUSSION

Sex assessment is a crucial step in skeletal remnants identification process in forensic anthropology because, it diminishes the percent of probable to half (Saukko and Knight, 2016). Three-dimensional (3D) magnetic resonance technique was found to be the most effective method of obtaining measurements as the films are quick, accurate and non-invasive (Muhammed et al., 2017). The aim of the current work was to develop sex identification from some parameters of the sacrum and coccyx by the use of MRI technique in Egyptian population. The results showed significant higher values of ASL, PSL, ASCL, PSCL, APD in males. Univariate discriminant function analysis revealed that ASL and PSL were the best parameters for sex estimation with 71.9% and 71.5% accuracy rates. Stepwise discriminant function analysis of all measurements of the sacrum and coccyx showed that PSL and ASL collectively produced 68.9% prediction rate.

Related researches provided widely varying measurements accuracy rates across different populations. Etli et al. (2019) analyzed measurements of sacrum and coccyx using computerized tomography technique in Turkish population and reported that, 78.8% accuracy for stepwise discriminant function analysis was achieved. Univariate discriminant analysis revealed that APD was the best for sex determination with (67.1%) accuracy then PSL (65.8%) and PSCL (64.6%).

Zhan et al. (2018) evaluated some sacrum and coccyx parameters by multidetector

computed tomography for estimation of sex in Chinese population and reported that the stepwise analysis of all used lengths gave a sex determination with 84.9% accuracy and a sex bias of 3.7%. Torimitsu et al. (2017) analyzed postmortem computed tomography images of 230 Japanese corpses and reported significant sex differences in PSCL and PSL, with 77.0% accuracy in univariate discriminant function analysis. Franklin et al. (2014) stated an accuracy rate of less than 70% of sex prediction in Western Australian population. They used 3D computed tomography images of sacral area. Also, Zech et al. (2012) study which used computed tomography scans of sacrum demonstrated an accuracy rate of less than 80% for sex estimation in Swiss individuals. The widely varying measurement accuracy rates across different populations suggesting racial and regional discrepancy in the width and length of the sacrum. Also, the above differences in sex determination rates may have contributed to a wide age range, as age and osteoporosis are from the factors that cause bone morphological changes. Subsequently, next researches should use wide but closely adjusted spectrum of age (Torimitsu et al., 2017). The population sample size might also contribute to various outcomes. So, by using larger sample size, it may be possible to achieve more accurate and less extreme outcomes (Etli et al., 2019).

V. CONCLUSION

This morphometric study concluded that sacral and coccygeal parameters are valuable for estimation of sex. Univariate discriminant function analysis revealed that ASL, PSL were the best parameters for sex determination with 71.9% and 71.5% accuracy. Stepwise discriminant function analysis of all parameters showed that PSL and ASL together showed 68.9% correct prediction rate. But these formulae could not be applied to other populations. So, further researches regarding sex estimation from sacrum and coccyx in different ethnicities are still needed to confirm the universality of this modality.

VI. REFERENCES

- Akhlaghi, M., Bakhtavar, K., Moarefdoost, J., Kamali, A. and Rafeifar, S. (2016): Frontal sinus parameters in computed tomography and sex determination. *Leg. Med. (Tokyo)*. 19: 22- 27.
- Benazzi, S., Stansfield, E., Milani, C. and Gruppioni, G. (2009): Geometric morphometric methods for three-dimensional virtual reconstruction of a fragmented cranium: the case of Angelo Poliziano. *Int. J. Leg. Med.*; 123: 333–344.
- El Morsi, D.A. and Al Hawary, A.A. (2013): Sex determination by the length of metacarpals and phalanges: X-ray study on Egyptian population. *J. Forensic Leg. Med.*20: 6-13.
- Etli, Y., Asirdizer, M., Hekimoglu, Y., Keskin, S. and Yavuz, A. (2019): Sex estimation from sacrum and coccyx with discriminant analyses and neural networks in an equally distributed population by age and sex. *Forensic Sci. Int.* 303: 109955.
- Franklin, D., Cardini, A., Flavel, A. and Marks, M.K. (2014): Morphometric analysis of pelvic sexual dimorphism in a contemporary Western Australian population. *Int. J. Legal. Med.* 128 (5):861-872. doi:10.1007/s00414-014-0999-8.
- Franklin, D., Flavel, A., Kuliukas, A., Cardini, A., Marks, M.K., Oxnard, C. et al. (2012): Estimation of sex from sternal measurements in a Western Australian population. *Forensic Sci. Int.*; 217: 230e1–230e5.
- Mamatha, H., Sandhya, Sushma R.K., Suhani S., Naveen Kumar (2012): significance of various sacral measurements in the determination of sex in south Indian population, *Int. J. Cur. Res. Rev.* 4: 112–118.
- Muhamed, R., Saralaya, V.V., Murlimanju, B.V. and Chettiar, G.K. (2017): In vivo magnetic resonance imaging morphometry of the patella bone in South Indian Population. *Anat. Cell Biol.* 50 (2): 99–103.
- Novak M. (2016): Sex assessment using the femur and tibia in Medieval skeletal remains from reland: discriminant function analysis. *Coll. Antropol.* 40 (1):17–22.

- Plochocki, J.H. (2011): Sexual dimorphism of anterior sacral curvature. *J. Forensic Sci.* 56 (1):161-164. doi:10.1111/j.1556-4029.2010.01455.x
- Ross, A.H., Ubelaker, D.H. and Kimmerle, E.H. (2011): Implications of dimorphism, population variation, and secular change in estimating population affinity in the Iberian Peninsula. *Forensic Sci. Int.*; 206: e1–214.
- Saukko, P. and Knight, B. (2016): The establishment of identity of human remains, in: P. Saukko, B. Knight (Eds.), *Knight's Forensic Pathology*, 4th ed., CRC Press, Boca Raton, pp. 95–132 Chapter 3.
- Torimitsu, S., Makino, Y., Saitoh, H., Sakuma, A., Ishii, N., Yajima, D., Inokuchi, G., Motomura, A., Chiba, F., Yamaguchi, R., Hashimoto, M., Hoshioka, Y. and Iwase, H. (2016): Sex estimation based on scapula analysis in a Japanese population using multidetector computed tomography. *Forensic Sci. Int.* 262; e1–285.
- Torimitsu, S., Makino, Y., Saitoh, H., Sakuma, A., Ishii, N., Yajima, D., Inokuchi, G., Motomura, A., Chiba, F., Yamaguchi, R., Hashimoto, M., Hoshioka, Y. and Iwase, H. (2017): Sex determination based on sacral and coccygeal measurements using multidetector computed tomography in a contemporary Japanese population. *J Forensic Radiol Imaging* 9:8–12
- Yasar Teke, H., Ünlütürk, Ö., Günaydin, E., Duran, S. and Özsoy S. (2018): Determining gender by taking measurements from magnetic resonance images of the patella. *J Forensic Leg Med.* 58:87-92. doi:10.1016/j.jflm.2018.05.002.
- Zech, W.D., Hatch, G., Siegenthaler, L., Thali, M.J. and Lösch, S. (2012): Sex determination from os sacrum by postmortem CT. *Forensic Science International.* 221(1-3):39-43. doi: 10.1016/j.forsciint.2012.03.022.
- Zhan, M.J., Fan, F., Qiu, L.R., Peng, Z., Zhang, K. and Deng, Z.H. (2018): Estimation of stature and sex from sacrum and coccyx measurements by multidetector computed tomography in Chinese. *Leg Med (Tokyo).* 34:21-26. doi:10.1016/j.legalmed.2018.07.003.

تحديد الجنس بناءً على قياسات العجز والعصص باستخدام التصوير بالرنين المغناطيسي في السكان المصريين

شيرين أحمد الخطيب ١ ، مروة السيد عبد الحميد ٢ ، منى سامي حامد ٣ ، مروة عبد المنعم عامر ١

١ أقسام الطب الشرعي و السموم الاكلينيكية، ٢ الاشعة التشخيصية ، ٣ طب المجتمع والصحة العامة ، كلية الطب ، جامعة الزقازيق ، مصر

المقدمة: تحديد الجنس هو خطوة مهمة في تحديد الشخص المجهول. تهدف الدراسة الحالية إلى تقييم اختلاف الشكل للعجز والعصص على حسب الجنس باستخدام التصوير بالرنين المغناطيسي في السكان المصريين. **الاشخاص و الطرق:** تمت الدراسة على ٢٣٠ مصرياً ١١٥ ذكر . ١١٥ أنثى) خضعوا للتصوير بالرنين المغناطيسي فوق العجز والعصص. تم الحصول على سبعة قياسات للأطوال وقياسين لزاوية كلا من العجز والعصص من خلال التصوير بالرنين المغناطيسي لكل شخص. **النتائج:** أظهرت القياسات بما في ذلك الطول العجزي الأمامي، والطول العجزي الخلفي، والطول العجزي العصصي الأمامي، والطول العجزي العصصي الخلفي والقطر الأمامي الخلفي لجسم الفقرة ، كانت أكبر بشكل ملحوظ في الذكور ، في حين لم يلاحظ أي اختلاف في اتساع جناح العجز، وزاوية المنحنى القطنية العجزية القصوى والزاوية العجزية القطنية بين الجنسين. أظهر تحليل الوظيفة التمييزية أحادية المتغير أن الطول العجزي الأمامي ساهم بشكل كبير في تحديد الجنس ، يليه والطول العجزي الخلفي بمعدلات دقة ٧١.٩٪ و ٧١.٥٪ على التوالي و أن هذين القياسين حددا التحليل التدريجي للعجز والعصص عن معدل تنبؤ صحيح بنسبة ٦٨.٩٪.

الاستنتاج و التوصيات: تشير هذه الدراسة إلى أن العجز والعصص مهمان لتحديد الجنس. وقد يكون مفيداً في تحديد جنس البقايا الهيكلية في السكان المصريين عندما تستخدم مع طرق إضافية ، مثل السمات المورفولوجية و تقييم العظام الأخرى المتاحة.