

Original Article

Sub chronic Toxicity of Pregabalin and Possible Fibrotic Changes in Ovaries, Kidneys, Heart, and Lungs of Female Rats

Noha E. Ebrahem,^{1*} Rania M.A Makboul², Mai M. Elkabsh², Nora Z. Abdellah¹, Eman S. Shaltout¹
Department of Forensic Medicine and Clinical Toxicology, Faculty of Medicine-Assiut University-Egypt¹, Department of Pathology, Faculty of Medicine-Assiut University-Egypt²

Abstract

*Corresponding author:

Noha Esmael Ebrahem
Department of Forensic
Medicine and Clinical
Toxicology, Faculty of
Medicine-Assiut
University-Egypt
E.mail:
nohaesmaiel@aun.edu.eg

Background: Pregabalin is an anti-epileptic drug that was approved as neuropathic pain therapy. Incidence of adverse reactions with pregabalin were reported to be related to dosage. **Aim:** This is a sub-chronic study to assess the possible fibrotic changes in lung, heart, kidney, and ovary as a result of long-term exposure to pregabalin. **Material and Methods:** Thirty female rats were divided equally into 3 groups (I, II and III). Group I (negative control group): received nothing. Group II (positive control): received 0.5 ml saline via gastric gavage daily for 8 weeks. 600 mg/kg body weight/day (a dose equivalent to 6 times the therapeutic dose

and 1/10th the maximum non-lethal dose) of Pregabalin was given to group III for 8 weeks. At the end of the study, rats were sacrificed. Kidney, lung heart and ovary specimens were taken for histopathological examination using Hematoxylin-eosin and Masson trichrome stain to demonstrate fibrosis. **Results:** The body weight of rats showed non significant difference between the 3 groups. Also weights of ovaries, kidneys, hearts, and lungs the 3 groups showed non significant difference. Ovarian tissue of female rats treated with pregabalin showed decreased number of follicles and increased stromal fibrosis. Interstitial fibrosis of kidney sections was also demonstrated. Heart sections of treated rats showed fibrosis between muscle fibers. Also, lung section showed patchy areas of dense fibrosis and inflammation.

Conclusion: The present study demonstrated ovarian, renal, pulmonary, and myocardial fibrosis in female rats after 8 weeks of daily oral administration of pregabalin. This raises a concern about the potential ability of pregabalin to induce fibrosis and the relationship between pregabalin induced fibrosis and organ failure.

Recommendations: Clinicians should assess the benefit-risk balance in patients before prescribing pregabalin; the patients should be screened for fibrosis before treatment and at regular intervals thereafter.

Keywords: Pregabalin, fibrosis, organ damage, lung, ovary, heart, kidney

I. INTRODUCTION

Pregabalin is a gabapentinoid antiepileptic approved by the Food and Drug Administration (FDA) and the European Medicines Agency (EMA) for treatment of neuropathic pain, which is a burdensome pain to treat. Pregabalin is also used for fibromyalgia and unapproved use for generalized anxiety disorders and migraine (Sendra et al., 2011, Toth, 2014 and Canos et al., 2016).

Pregabalin is an analogue of the neurotransmitter γ -aminobutyric acid (Tambon et al., 2021). The exact mechanism of pregabalin's action is still unclear. However, the presumed mechanism of its analgesic action is thought to be via reduction in neurotransmitters' release. The main binding target for pregabalin is $\alpha 2$ - δ (type 1) receptor. Binding of pregabalin to the $\alpha 2$ - δ subunit of voltage-gated calcium channels results in alteration in the kinetics and voltage dependence of calcium currents (Gajraj, 2007 & Nanou and Catteral., 2018). These alterations reduce calcium influx at nerve terminals, reduces the release of many neurotransmitters, including glutamate, noradrenaline, calcitonin, gene-related peptide, and substance P (Dooley et al., 2000).

Incidence of adverse reactions with pregabalin were reported to be related to dosage, with more occurrence in patients receiving 600 mg/day (Freeman et al., 2008). Retroperitoneal fibrosis, myelofibrosis and lung fibrosis were observed among the rare adverse reactions of pregabalin use during the clinical studies (Chen et al., 2011). Generally, fibrosis might be detected in various organs, including heart, liver, lung, and kidney. Fibrosis is characterized by excessive proliferation of fibroblasts and deposition of extracellular matrix. Advanced fibrosis can lead to decline of organs' functions or even failure (Zhou et al., 2017). The exact mechanism of fibrosis caused by pregabalin is not reported in research. Furthermore, there is no sufficient data regarding the possibility of pregabalin as being a potential inducer of fibrosis in other tissues.

The aim of this research was to observe histopathological changes and fibrosis in ovaries, kidneys, heart and lungs of females rats after sub chronic oral administration of pregabalin

II. MATERIAL and METHODS:

Drugs and chemicals

Pregabalin (Lyrica 600 mg capsules) was purchased from Pfizer, Egypt

Animals

Thirty adult female albino rats aged three weeks old were used (200-230 gm weight). The animals were obtained from animal house in the Faculty of Medicine, Assiut University, Egypt, they were permitted to accommodate 2 weeks then housed in special cages and maintained in regular laboratory conditions {Temperature (22-26°C), humidity (50-60%), artificial illumination (12h light/dark cycles), well-ventilated, and free of contamination, and fed a standard balanced diet & water ad libitum}. Rats were randomized into 3 groups (10 rats for each group);

- **Group I (negative control group):** received nothing.
- **Group II (positive control):** received 0.5 ml saline via gastric gavage daily for 8 weeks.
- **Group III (pregabalin treated group):** received 600 mg/kg of pregabalin, a dose equivalent to 6 times the therapeutic dose and 1/10th the maximum non-lethal dose. Pregabalin was dissolved in 0.5ml saline and given via gastric gavage daily for 8 weeks.

Methods

Weights of animals were recorded during and at the end of the

study. At the end of the study, all rats were anaesthetized with 50 mg/kg intraperitoneal thiopental and sacrificed (**Gargiulo et al., 2012**). Ovaries, kidneys, heart and lungs specimens were collected for examination after weighing of organs. All histological procedures were carried out using standard laboratory approaches. The tissues were fixed in 10% paraformaldehyde solution, embedded in paraffin blocks, and cut into 5 mm thick slices that were subsequently mounted onto glass slides. Hematoxylin-eosin (HE) staining was done. Masson trichrome stain was used to demonstrate fibrosis. All slices were inspected carefully, and photographs were taken using an optical microscope (Olympus BX50, Moticam 2306, Japan).

Statistical analysis

Data were expressed as means \pm SD. One-way ANNOVA was used to assess the statistical significance of differences between the experimental groups. A p-value less than 0.05 was regarded to be statistically significant. All statistical analysis was performed using SPSS 26.0.

Ethical considerations:

The research experiment was conducted after ethical approval as stated by the Guidelines of the National Institute of Health for

Animal Care followed within the Faculty of Medicine, according to referenced authority (ILAR, 2011).

III. RESULTS

Results of Body weight and organs weights: The results of the present

study revealed that body weight of rats showed non-significant difference between the 3 groups. Also weights of ovaries, kidneys, hearts, and lungs of the 3 groups showed non-significant difference Table (1).

Table (1): Statistical comparison of body and organs' weights of the control groups and pregabalin treated group by ANOVA one way Test

	Body weight	Ovary	Kidney	Heart	Lung
Group (I)	215.78±10.18	33.86±1.8	1.6±0.8	1.58±0.55	2.02±.127
Group (II)	216±11.8	32.74±2.78	1.63±.08	1.56±.073	2.05±.823
Group (III)	218.2±5.76	32.68±1.71	1.55±.76	1.55±.53	1.98±.70
Significance	0.824	0.4	0.110	0.576	0.568

Data are expressed as Mean± SEM of 10 rats per group. Data were analyzed by one-way ANOVA followed by Bonferoni *post hoc test*

Histopathological results: Histopathological examination of rats' tissues from group (I) and group (II) showed normal results and group (I) is referred as the control group.

a- Hematoxylin and Eosin:

Histopathological examination of ovarian tissue sections from the ovaries of normal control rats revealed numerous follicles and normal ovarian stroma with well-defined zona granulosa surrounding the oocytes. Ovarian tissue sections of rats treated with pregabalin showed decreased number of follicles and nearly all of them were atretic (Figure 1). Sections of kidney of normal control rats demonstrated normal glomeruli and tubules. While sections from kidney of

rats treated by pregabalin showed dilatation of renal tubules with casts inside them (Figure 2).

Section from heart of normal control rat demonstrated normal muscle bundles without intervening fibrosis. Also, sections from heart of treated rat stained showed no obvious histological fibrosis (Figure 3).

Section from lung of normal control rat demonstrated normal alveoli and bronchiole, While Sections from lung of rats treated with pregabalin showed interstitial pneumonia; patchy distribution of areas expressing dense fibrosis and inflammation. The inflammation affecting the lung parenchyma showed mixed acute and chronic criteria together with fibrosis. Cysts lined by

respiratory epithelium containing proteinaceous material were also demonstrated together with fibrosis affecting the lung parenchyma (Figure 4).

b- Masson trichrome stain

Masson trichrome stained section of ovary of normal control rat with normal ovarian stroma. While Masson trichrome stained sections of ovaries of pregabalin treated rats showed increased fibrosis in ovarian stroma (Figure 1). Sections of kidney of normal control rats stained by Masson trichrome stain revealed no interstitial fibrosis while Masson trichrome stained section from kidney of treated rat showed interstitial fibrosis (Figure 2).

Section from heart of normal control rats revealed normal muscle bundles without intervening fibrosis, while section from heart of treated rats stained by Masson trichrome stain showed fibrosis between muscle fibers (Figure 3). Section of lung of normal control rat stained by Masson trichrome stain demonstrated no interstitial fibrosis while: Masson trichrome stained section from lung of treated rat showed interstitial fibrosis demonstrated (Figure 4).

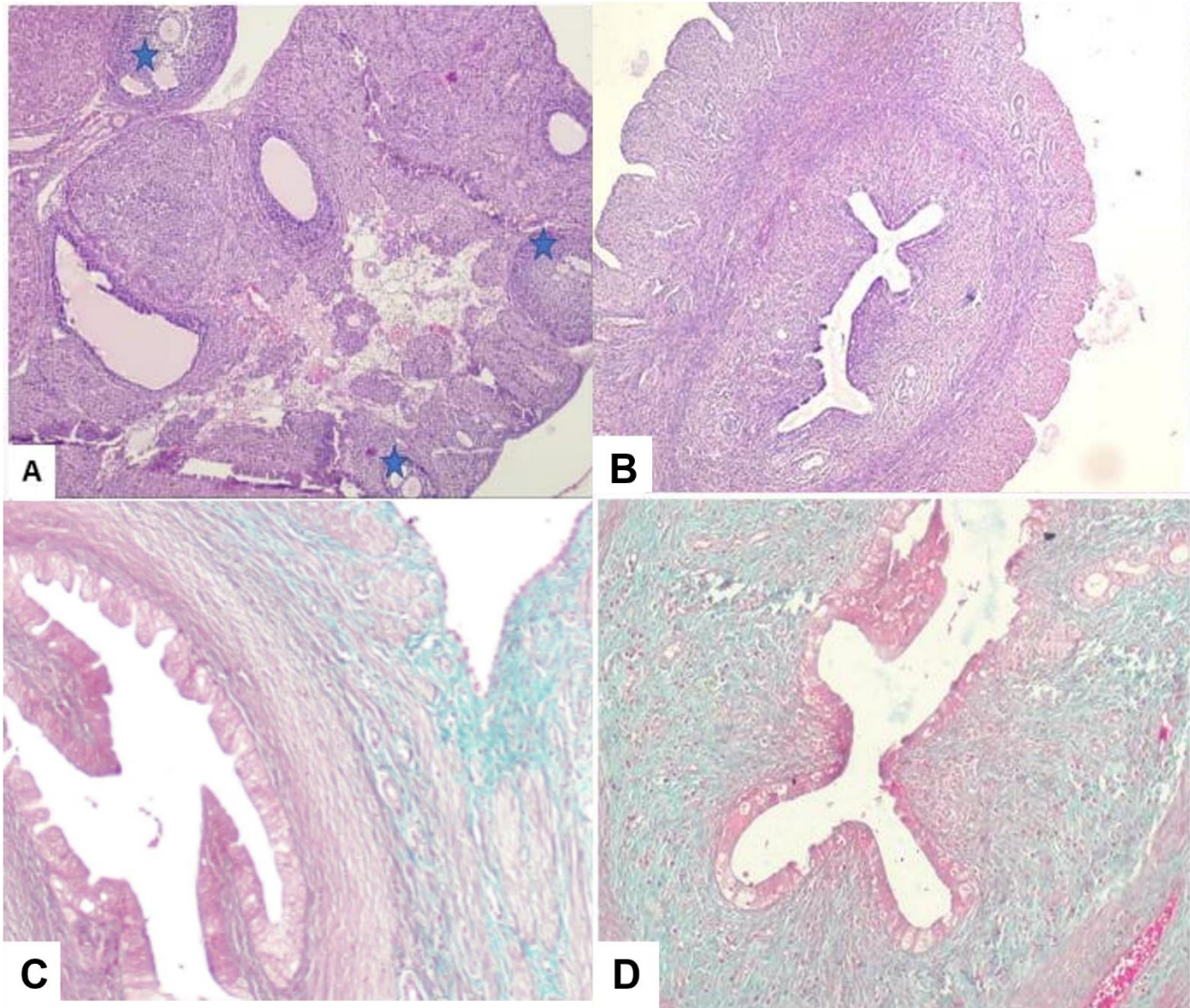


Figure (1): A: Section from the ovary of control rat stained by H&E stain revealed numerous follicles (blue asterisks) and normal ovarian stroma (40x). B: Sections from ovary of rat treated by pregabalin stained by H&E stain showing decreased number of follicles and nearly all of them are atretic (40x). C: Masson trichrome stained section of ovary of control rat with normal ovarian stroma. (100x) D: Masson trichrome stained section of pregabalin treated rat showing increased fibrosis in ovarian stroma demonstrated by blue color (100x).

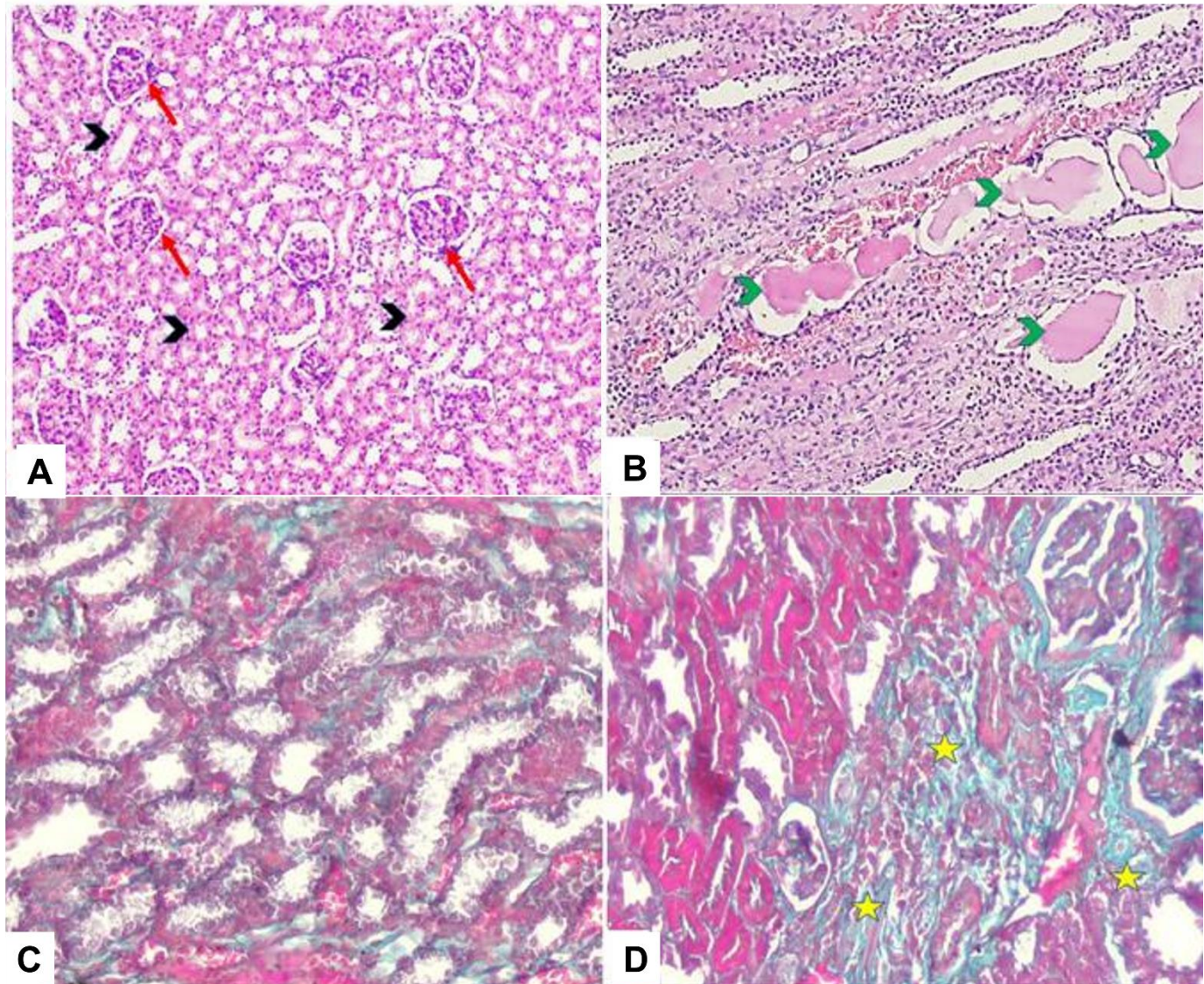


Figure (2): A: Sections of kidney of control rats stained by H&E stain showing normal glomeruli (red arrow) and tubules (black arrowhead) (100x). B: Section from kidney of rat treated by pregabalin stained by H&E stain showing dilatation of renal tubules with casts inside them (green arrowhead) (100x). C: Section of kidney of control rats stained by Masson trichrome stain showing no interstitial fibrosis in normal kidney (no blue staining) (200x). D: Masson trichrome stained section from kidney of treated rats showing interstitial fibrosis demonstrated as blue color (yellow asterisks) (200x).

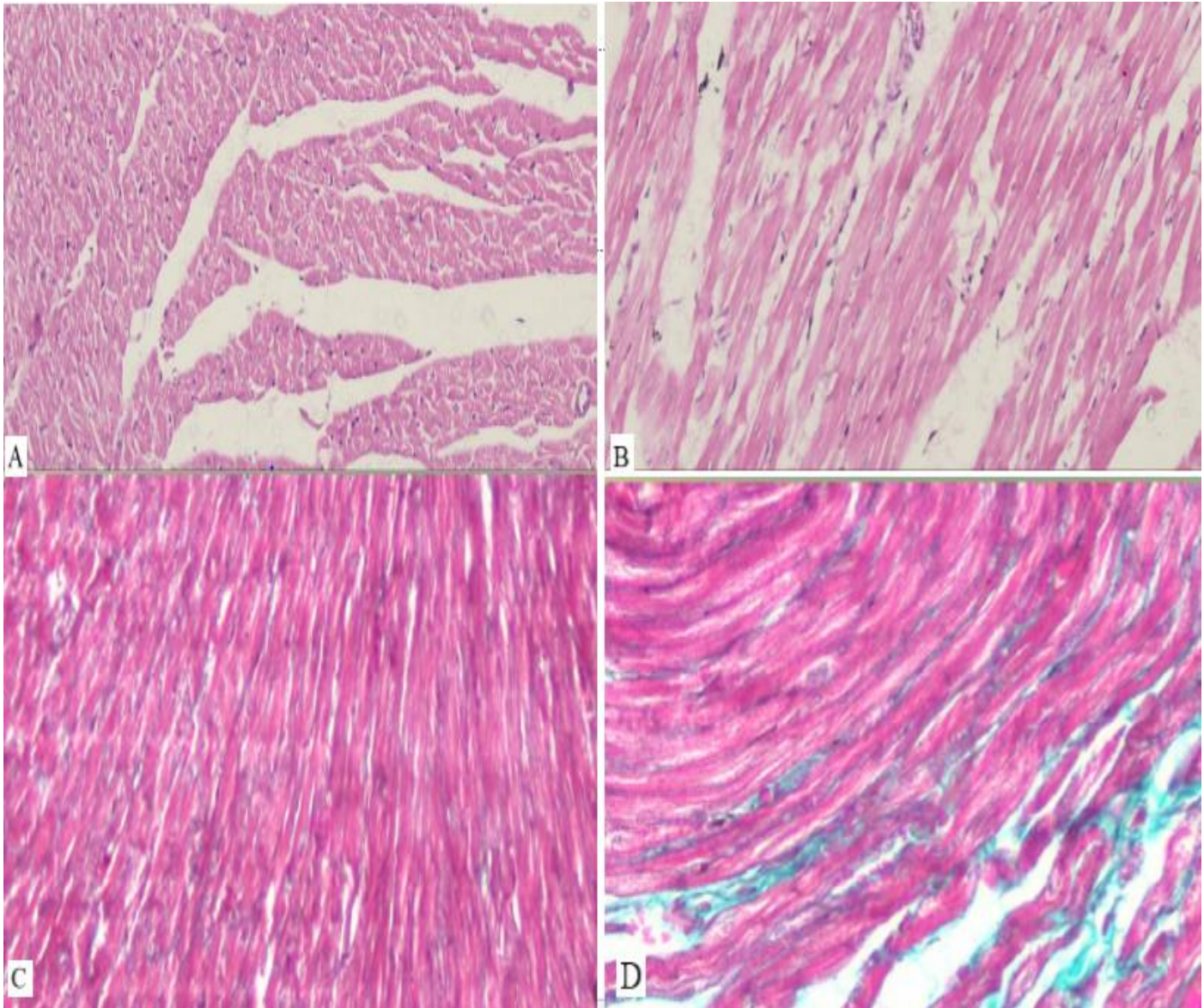


Figure (3): A: Section from heart of control rat stained by H&E stain showing normal muscle bundles without intervening fibrosis (40x). B: Section from heart of treated rat stained by H&E stain with no obvious histological fibrosis (100x). C: Section from heart of control rat stained by Masson trichrome stain showing without fibrosis (no blue staining) (400x). D: Section from heart of treated rat stained by Masson trichrome stain showing fibrosis between muscle fibers (blue staining) (400x).

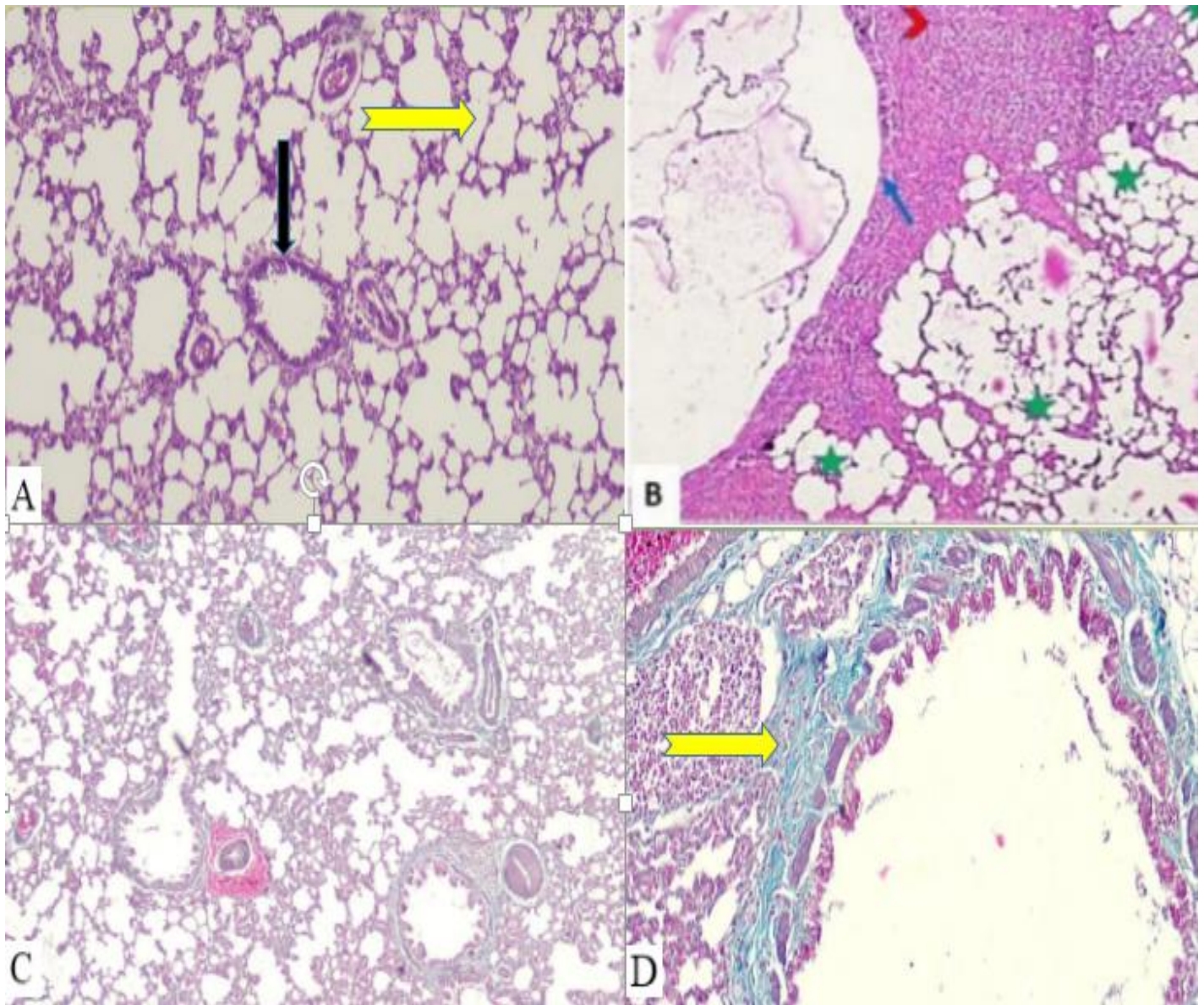


Figure (4): A: Section from lung of control rat stained by H&E stain showing normal alveoli (yellow arrowhead) and bronchiole (black arrow) (100x). B: Section from lung of rat treated by pregabalin stained by H&E stain showing interstitial pneumonia; patchy distribution; areas expressing dense fibrosis and inflammation (red arrowhead), cysts lined by respiratory epithelium (blue arrow) and honeycomb change (green asterisks) (100x). C: Section of lung of control rat stained by Masson trichrome stain showing no interstitial fibrosis (no blue staining) (200x). D: Masson trichrome stained section from lung of treated rat showing interstitial fibrosis demonstrated as blue color (yellow arrow) (200x).

IV. DISCUSSION

Pregabalin is a widely used drug for treating neuropathic pain (**Verma et al., 2014**). Pregabalin has common adverse effects such as dizziness, somnolence, blurry vision, dry mouth and peripheral edema (**Toth, 2014**). However, fibrosis is reported as a rare side effect (**Chen et al., 2011**). In rats; repeated dose toxicity studies reported adverse effects on male reproductive organs in the form of oligospermia, epididymis interstitial fibrosis, and prostatic atrophy (**EMA 2004**). There are a few reports addressing a potential relationship between pregabalin induced fibrosis and organ failure. The clinical effects of fibrosis often appear after a long duration, Thus diagnosis of organ fibrosis may come too late after damage of organs (**Wynn, 2008**).

In the present study; ovarian tissue of female rats treated with pregabalin for 8 weeks showed decreased number of follicles and increased stromal fibrosis. **Tawfeeq et al. (2016)** reported that daily oral ingestion of 150 mg and 300 mg/kg of pregabalin causes unfavorable effects on the ovarian tissues and the fertility of female rats. Diffuse ovarian fibrosis represents a considerable risk for diminished fertility (**Zhou et al., 2017**).

The present results also demonstrated interstitial fibrosis of kidney sections of rats treated by pregabalin. Furthermore, dilatation of renal tubules with casts inside them was observed. There are no previous animal studies available reporting renal fibrosis after administration of pregabalin. However, cases of pregabalin induced neurotoxicity in chronic kidney disease patients were reported (**Lee et al., 2011**). Fibrosis can destroy the renal parenchymal tissue leading to progressive decline of kidney function and eventually failure. It was reported that tubulointerstitial fibrosis is an essential feature of chronic renal failure (Yu et al., 2010 and Wang et al., 2021). Drugs and metabolites might accumulate in subjects having chronic renal impairment with reduced glomerular functions. Pregabalin is not metabolized in liver and is mainly excreted unchanged in the urine by kidneys (**Bockbrader et al., 2012**). The manufacturers of pregabalin forms list dosing recommendations relative to creatinine clearance for the medications (**Raouf et al., 2017**).

Heart sections of treated rats in the current study showed fibrosis between muscle fibers. In a few treated monkeys from the 4-week pivotal study, focal myocardial necrosis or fibrosis were

observed at 3-4 times human dose (EMA, 2004). Furthermore, Acute decompensated heart failure and acute kidney injury were reported in an elderly woman with a history of heart failure (class I) who was taking pregabalin presented and discontinuation of pregabalin together with supportive treatment, patient's symptoms improved rapidly (Lyu *et al.*, 2017). However, A cohort study demonstrated no association between the use of pregabalin and increased risk of exacerbating heart condition, compared with gabapentin and duloxetine (Lund *et al.*, 2020). Cardiac fibrosis is a major causes of heart failure. There are two types of myocardial fibrosis: replacement fibrosis as a result of myocyte necrosis after myocardial infarction. Other conditions associated with replacement fibrosis include hypertrophic cardiomyopathy, myocarditis, and toxic cardiomyopathies. The second type is interstitial fibrosis which might be reactive or infiltrative interstitial fibrosis. Myofibroblasts are the most prominent cells involved in myocardial fibrosis. The precursor cells of Myofibroblasts are activated by different causes such as myocardial injuries, including toxic insult (Ambale-Venkatesh and Lima, 2015 & Liu *et al.*, 2017).

Sections from lung of rats treated with pregabalin in the present study, showed patchy areas of dense fibrosis and inflammation. Lung fibrosis is listed as a

rare side effect of pregabalin use. Lung fibrosis is characterized by the accumulation of excessive connective tissue. Its causes include chronic administration of some drugs, exposure to certain environmental factors and infections (Daba *et al.*, 2004).

The mechanism of drug induced fibrosis is not fully understood. However, pregabalin was reported to increase blood concentration of serotonin in therapeutic dose ranges (Jellestad *et al.*, 2016) Serotonin (5-hydroxytryptamine or 5-HT) is a part of many biological processes including wound healing in skin and organs such as liver, lung and heart. yet, in case of chronic injury, signaling of 5-HT can have unfortunate consequences and stimulate deviant wound healing resulting in tissue fibrosis and impaired organ regeneration (Mann and Oakley, 2013). 5-HT aggravate pulmonary fibrosis by stimulation of inflammation, exudation, oxidative stress, and overexpression of fibrosis-associated genes in the lung tissues (Zhang *et al.*, 2018). Furthermore, Pregabalin was reported to bind with high affinity to the voltage-gated calcium channel $\alpha_2\delta$ subunit (Li *et al.*, 2011). An abnormal Ca^{2+} profile has been observed in cystic fibrosis cells (Rimessi *et al.*, 2021).

V. CONCLUSIONS

The present research demonstrated ovarian, pulmonary, renal and myocardial fibrosis in female rats after 8 weeks of daily oral administration of pregabalin. This raises a concern about the potential ability of pregabalin to induce fibrosis and the relationship between pregabalin induced fibrosis and organ failure.

VI. RECOMMENDATIONS

Future research is needed to understand the mechanism of fibrosis caused by pregabalin and its relation to actions of serotonin signaling. Clinicians should assess the benefit-risk balance in the individual patient before prescribing pregabalin; the patients should be screened for fibrosis before treatment and at regular intervals thereafter.

List of abbreviations

Not applicable

VII. REFERENCES

1. Ambale-Venkatesh B., Lima J. A. (2015): Cardiac MRI: a central prognostic tool in myocardial fibrosis. *Nature Reviews Cardiology*. 12: 18–29.
2. Bockbrader H.N., Wesche D., Miller R., Chapel S., Janiczek N., Burger PA. (2012): A Comparison of the Pharmacokinetics and Pharmacodynamics of Pregabalin and Gabapentin. *Clinical Pharmacokinetics*. 49(10): 661–669.
3. Canos A., Cort L., Fernández Y., Rovira V., Pallarés J., Barberá M., Morales-Suárez-Varela M. (2016): Preventive analgesia with pregabalin in neuropathic pain from “failed back surgery syndrome”: Assessment of sleep quality and disability. *Pain Medicine (United States)*, 17(2):344–352.
4. Chen M., Vijay V., Shi Q., Liu Z., Fang H., Tong W. (2011): FDA-approved drug labeling for the study of drug-induced liver injury. *Drug Discovery Today*.(15-16):697-703.
5. Daba M.H., El-Tahir K.E., Al-Arifi M.N., Gubara O.A. (2004): Drug-induced pulmonary fibrosis. *Saudi Medical Journal*. 25(6):700-706.
6. Dooley D.J., Donovan C.M., Pugsley T.A. (2000): Stimulus-dependent modulation of [3H]norepinephrine release from rat neocortical slices by gabapentin and pregabalin. *Journal of Pharmacology and Experimental Therapeutics*. 295(3): 1086–1093.
7. EMA (European Medicines Agency) (2004): the European public assessment report (EPAR) for Lyrica. available at: https://www.ema.europa.eu/en/documents/scientific-discussion/lyrica-epar-scientific-discussion_en.pdf
8. Freeman R., Durso-DeCruz E., Emir

- B. (2008): Efficacy, Safety, and Tolerability of Pregabalin Treatment for Painful Diabetic Peripheral Neuropathy, findings from seven randomized, controlled trials across a range of doses, *Diabetes Care*, 31(7):1448-1454.
9. Gajraj N.M. (2007): Pregabalin: Pharmacology and use in pain management. *Anesthesia & Analgesia*. 105(6):1805-1815.
10. Gargiulo S., Greco A., Gramanzini M., Esposito S., Affuso A., Brunetti A., Vesce G.(2012): Mice anesthesia, analgesia, and care, Part I: anesthetic considerations in preclinical research. *the Institute for Laboratory Animal Research Journal*. 53(1):E55-69.
11. ILAR (Institute of Laboratory Animal Resources) (2011): Guide for the Care and Use of Laboratory Animals. 8th edition. National Academy Press, Washington DC, PP. 21-55.
12. Jellestad L., Stocker L., Jenewein J., Boettger S. (2016): Serotonin Syndrome after Initiation of Pregabalin on a Stable Regimen of Antidepressant Medication. *International Journal of Medical and Pharmaceutical Case Reports*. 7(5): 1-4.
13. Lee D.W., Lee H.J., Kim H.J., Chang S.H., Park D.J. (2011): Two cases of pregabalin neurotoxicity in chronic kidney disease patients. *NDT Plus*, 4(2):138.
14. Li Z., Taylor C.P., Weber M., Piechan J., Prior F., Bian F., Cui M., Hoffman D., Donevan S. (2011): Pregabalin is a potent and selective ligand for $\alpha 2\delta-1$ and $\alpha 2\delta-2$ calcium channel subunits. *The European Journal of Pharmacology*. 667(1-3); 80-90.
15. Lund M., Poulsen G., Pasternak B., Worm Andersson N., Melbye M., Svanström H. (2020): Use of Pregabalin and Worsening Heart Failure: A Nationwide Cohort Study. *Drug Safety*. 43(10):1035-1044.
16. Liu T., Song D., Dong J., Zhu P., Liu J., Liu W., Ma X., Zhao L., Ling S. (2017): Current Understanding of the Pathophysiology of Myocardial Fibrosis and Its Quantitative Assessment in Heart Failure. *Frontiers in physiology*, 8 (238): 1-13.
17. Lyu T., Wu H., GOh E. (2017): Emergency Medicine and Pregabalin-Induced Heart Failure: A New Entity?, *SM Emergency Medicine and Critical Care*. 1(2):2-4.
18. Mann D.A., Oakley F. (2013): Serotonin paracrine signaling in tissue fibrosis. *Biochimica et Biophysica Acta*, 1832(7); 905-910.
19. Nanou E., Catterall W.A. (2018):

- Calcium Channels, Synaptic Plasticity, and Neuropsychiatric Disease. *Neuron*. 2;98(3):466-481.
20. Raouf M., Atkinson T.J., Crumb M.W., Fudin J. (2017): Rational dosing of gabapentin and pregabalin in chronic kidney disease. *Journal of Pain Research*. 10:275-278.
21. Rimessi A., Vitto V.M., Patergnani S., Pinton P. (2021): Update on Calcium Signaling in Cystic Fibrosis Lung Disease. *Frontiers in Pharmacology*. 12:581-645.
22. Sendra J.M., Junyent T.T., Pellicer M.J. (2011): Pregabalin-induced hepatotoxicity. *Annals of Pharmacotherapy*. 45(6):e32.
23. Tawfeeq E.N., Yanzeel J.H., Fakhrildin M.R. (2016): Effect of pregabalin on ovary tissue of albino female rats. *World journal of experimental biosciences*. 4(1):79–82.
24. Tambon M., Ponté C., Jouanjus E., Fouilhé N., Micallef J., Lapeyre-Mestre M., French Addictovigilance Network (FAN) (2021): Gabapentinoid Abuse in France: Evidence on Health Consequences and New Points of Vigilance. *Frontiers in psychiatry*. 12, 639780.
25. Toth C. (2014): Pregabalin: latest safety evidence and clinical implications for the management of neuropathic pain. *Therapeutic Advances in Drug Safety*. 5(1): 38–56.
26. Verma V., Singh N., Singh Jaggi A. (2014): Send Orders for Reprints to reprints@benthamscience.net
Pregabalin in Neuropathic Pain: Evidences and Possible Mechanisms. *Current Neuropharmacology*. 12(1):44-56.
27. Wang X., Chen J., Xu J., Xie J., Harris D.H., Zheng G. (2021): The Role of Macrophages in Kidney Fibrosis. *Frontiers in Physiology*. 6(12):1-13.
28. Wynn T.A. (2008): Cellular and molecular mechanisms of fibrosis. *Journal of Pathology*. 214(2):199–210.
29. Zhang J., Cui R., Feng Y., Gao W., Bi J., Li Z., Liu C. (2018): Serotonin exhibits accelerated bleomycin-induced pulmonary fibrosis through TPH1 knockout mouse experiments. *Mediators of Inflammation*. 2018:7967868:1-10
30. Zhou F., Shi L.B., Zhang S.Y. (2017): Ovarian Fibrosis: A Phenomenon of Concern. *Chinese medical journal*. 130(3): 365–371.

التسمم المزمن قصير المدى للبريجابالين والتغيرات الليفية المحتملة في أنسجة المبيض، الكلى، القلب، الرئة، لإناث الجرذان

نها إسماعيل إبراهيم¹، رانيا مقبول أحمد²، مي محمد الكبش²، نوره زيدان عبد الله¹،
إيمان صلاح الدين شلتوت¹

قسم الطب الشرعي والسموم الاكلينيكية - كلية الطب - جامعة اسيوط- جمهورية مصرالعربية¹، قسم الباثولوجي
بكلية الطب - جامعة اسيوط -جمهورية مصرالعربية²

الملخص العربي

المقدمة: البريجابالين هو أحد أدوية علاج الصرع والذي تمت الموافقة عليه كعلاج لألم الأعصاب. **الهدف من الدراسة:** هو تقييم التغيرات الليفية المحتملة أنسجة المبيض، الكلى، القلب، الرئة لإناث الجرذان نتيجة التعرض طويل الأمد للبريجابالين. **طريقة البحث:** تم استخدام ثلاثين من إناث الجرذان وتم تقسيمهم بالتساوي إلى 3 مجموعات. المجموعة الأولى لم تتلقى أية أدوية (المجموعة الضابطة السلبية)، المجموعة الثانية تم اعطائها 0.5 ملليتر من محلول الملح عن طريق الفم لمدة 8 أسابيع (المجموعة الضابطة الإيجابية). أما المجموعة الثالثة فتم إعطاء 600 مجم / كجم من وزن الجسم / يوم من البريجابالين لمدة 8 أسابيع. في نهاية الدراسة، تم تشريح الفئران و أخذ عينات من أنسجة المبيض، الكلى والرئة والقلب للفحص الهستوباثولوجي. **النتائج:** وقد اظهرت النتائج عدم وجود فروق ذات دلالة إحصائية في أوزان الجرذان وأوزان الأعضاء محل الدراسة (المبيض، الكلى، القلب، الرئة) بين المجموعات الثلاث. الفحص الهستوباثولوجي لأنسجة المبيض المعالجة بالبريجابالين اظهر انخفاض عدد الجريب المبيضي وزيادة التليف اللحمي. كما لوحظ وجود تليف بين الأنسجة الخلالية لأقسام الكلى. فيما أظهرت مقاطع تشريحية من الرئة مناطق متقطعة من التليف والالتهابات الكثيفة. أيضا أظهرت أنسجة القلب تليفاً خلالي بين ألياف العضلات. **الاستنتاج:** أظهرت الدراسة حدوث تليف في أنسجة المبيض و الكلى و القلب والرئة لإناث الجرذان بعد تلقي البريجابالين عن طريق الفم لمدة ثمانية أسابيع مما يلفت الاهتمام فيما اذا كان هناك ارتباط محتمل بين استخدام البريجابالين وحدث تليف بأنسجة الأعضاء. **التوصيات:** يجب على الأطباء تقييم وموازنة بين الفوائد والمخاطر قبل وصف البريجابالين للمرضى؛ كما يمكن أن يتم فحص المرضى لاكتشاف أي تليف بالأعضاء قبل العلاج وعلى فترات منتظمة أثناء العلاج بالبريجابالين.