



Original article

The role of N-Acetyl Cysteine in ameliorating Doxorubicin induced cardiotoxicity in rats

Emad Altaher¹, Abdel Hady R.H.², Safaa M. George², Abeer Refaiy³, Rania A.Radwan⁴

¹Department of Forensic Medicine and Clinical Toxicology, Faculty of Medicine, Aswan University, Egypt

²Department of Forensic Medicine and Clinical Toxicology, Faculty of Medicine, Assiut University, Egypt

³Department of Pathology, Faculty of Medicine, Assiut University, Egypt

⁴Department of Forensic Medicine and Clinical. Toxicology, Faculty of Medicine, Sohag University, Egypt

Abstract

*Corresponding author

Emad Altaher

e-mail: emadeldeen@aswu.edu.eg

Doxorubicin (DOX) is an anthracycline antibiotic and a quinone-containing chemotherapeutic drug used for various types of solid and hematological cancers. However, it causes many toxic side effects,

including cardiac, renal, hematological, and testicular. The current study investigated the prophylactic and ameliorative effect of n-acetylcysteine (NAC) against DOX-induced cardiotoxicity in albino rats. Sixty rats were divided into six groups. Negative Control group: rats received food pellets and tap water ad libitum. NAC treated (positive control) group: rats received NAC (400 mg/kg/p.o.) Every other day for 28 days. DOX-treated group: rats received DOX (5 mg/kg, i.p.) for four weeks on days 1, 7, 14 and 21. NAC pre-treated group: rats received NAC (400 mg/kg/p.o.) every other day one week earlier and then along with DOX (5 mg/kg/ i.p.) for the next four weeks on days 1, 7, 14 and 21). NAC1+DOX treated group : rats received NAC (400 mg/kg/ p.o.) every other day started at the first day of the experiment till the end of the experiment and DOX (5 mg/kg/ i.p.) for four weeks on day 1, 7, 14 and 21. NAC2+DOX treated group: rats received NAC (800 mg/kg, p.o.) every other day started at the first day of the experiment till the end of the experiment and DOX (5 mg/kg, i.p.) for four weeks on day 1, 7, 14 and 21. The present **results** showed a significant increase in the serum levels of LDH, CK-MB, CTn-I, plasma level of malondialdehyde (MDA). Whilst, plasma level of reduced glutathione (GSH) and Erythrocyte lysate level of glutathione peroxidase (GSH-Px) were significantly decreased. Moreover, there were histopathological abnormalities in the cardiac tissue of DOX-treated rats, was recognized by disrupted cardiac muscle fibers and foci of degeneration of the myocardium. The present study demonstrated that NAC has a cardioprotective effect on the cardiac damage induced by DOX, through inhibition of inflammation and oxidative stress. This cardio protective effect was more pronounced in both NAC pre-treated and concurrent (NAC1+DOX & NAC2+DOX), as it produced a significant increase in GSH and GSH-Px levels, a significant decrease in MDA, LDH, CK-MB, and CTn-I, and more improvement in the histopathological abnormalities, without a significant difference either between NAC pre-treated & concurrent groups or between groups of concurrent one (NAC1+DOX & NAC2+DOX).

Keywords: Doxorubicin; N-Acetyl cysteine; cardiotoxicity; Oxidative stress.

I. INTRODUCTION:

Doxorubicin (DOX) is one of the most effective and extensively used chemotherapeutic agents for different types of solid and hematological tumors. Unfortunately, the usage of this drug leads to severe side effects of cardiotoxicity (Yu *et al.*, 2018).

Cardiotoxicity is one of the hazardous chemotherapy side effects and was defined as a reduction in left ventricular ejection fraction (LVEF) of more than 10% to a value lower than 50% (Cardinale *et al.*, 2015).

DOX acts by numerous mechanisms of action. Currently, it is unclear which of these mechanisms are the most responsible for its associated cardiac toxicity. Many articles support that the generation of reactive oxygen species (ROS) due to DOX treatment and its consequential lipid peroxidation, calcium dysregulation, and intervention in energy transfer could cause heart failure (Winningmahl *et al.*, 2019).

While the molecular processes behind the anticancer effects of anthracyclines (ANTs) such as doxorubicin are well known and studied, the mechanisms underlying their cardiotoxic effects are still poorly understood and controversial. It is well established that ANTs do their anticancer action by directly targeting and hindering topoisomerase 2 (Top2) in cancer cells, more specifically the 2 α isoform, halting DNA transcription, and replication (Murabito *et al.*, 2020).

N-acetylcysteine (NAC), a precursor of reduced glutathione (GSH), was widely used as an antioxidant against reactive oxygen species (ROS) in several disorders related to oxidative stress (Teodorczyk and Schmidt, 2014).

N-Acetylcysteine (NAC) is an acetylated precursor of the amino acid L-cysteine. It used as an antidote for paracetamol intoxication and as a mucolytic agent (Elbini *et al.*, 2016).

This study aimed to evaluate cardiac toxicity of doxorubicin at biochemical and histopathological levels in rats; and assessment of the protective role of N-Acetylcysteine in both pre-treatment and co-administration with doxorubicin against its induced cardiotoxicity.

II. Materials & Methods

1) Drugs

1-N-acetyl-cysteine ($C_5H_9NO_3S$) was purchased from (AK Scientific, Inc. company) with purity 98%, Stored at 2 to 8°C.

2-Doxorubicin (Adriblastina vials, Pharmacia Italia S.P.A., Italy) was purchased as an injectable commercial product. Each vial contains doxorubicin hydrochloride as a 50 mg dried powder stored at 2 -8°C. The contents of each vial were freshly dissolved in a sterile saline solution just before use in 25 ml so each one ml contains 2mg DOX and the rest is discarded after use.

2) Chemicals and reagents

a) Cardiac markers assessment Kits

Lactate dehydrogenase enzyme (LDH) Kits were purchased from the Egyptian Company of Biotechnology, EGYPT.

(CK-MB) kits VITRO KINETIC SCIENT Germany

Troponin I ELISA Kits were purchased from IMMUNOSPEC Corporation, USA, CAT. No. E29- 061.

b) Oxidative stress parameters

I- Lipid peroxide (Malondialdehyde) Kits was purchased from Bio-diagnostic Company, Egypt CAT. No. , MD 25 29.

II- Glutathione Reduced (GSH) Kits were purchased from Bio-diagnostic company. Egypt CAT No. GR 25 11.

III- Glutathione peroxidase (GSH-Px) Tests were purchased from Bio-diagnostic Company. Egypt CAT. No. GP 25 24.

3) Animals:

The study was carried out on (60) male adult (two-month-old) albino rats, with an average weight (150-200 grams). They were obtained from the animal house of the national center for research, Giza, Egypt. They were housed in an animal house, Faculty of Medicine, Assiut University, Egypt. The animals were kept under routine healthy laboratory conditions and were fed normal food pellets ad libitum and tapwater, with room temperature being maintained

(25±2 °C). The ethics and husbandry conditions of animal research were considered according to the guidelines approved by the ethical committee of Aswan Faculty of Medicine, Aswan University.

III. Experimental design:

The rats were divided into six groups ten rats each. The experiment lasted for five weeks to investigate the cardiac toxicity induced by DOX and protective effects of NAC on heart organs.

Animal grouping

- Group A: (negative control): Rats have received food pellets and tap water ad libitum.

- Group B: (NAC treated group): Rats were received NAC orally by gastric tube at a dose of 400 mg/kg every other day for four weeks (*Dauletbaev et al., 2009*).

- Group C: Rats were received DOX intraperitoneal (i.p.) at a dose of 5mg/kg once a week for four weeks days (*Kulkarni and Swamy, 2015*).

- Group D: (NAC pre-treated) Rats were received NAC one week earlier orally by gastric tube at a dose of 400mg/kg every other day for 35 days and then with (DOX) 5mg/kg I.p. once for four weeks from the second week.

- Group E: Concurrent treatment (NAC1 + DOX) Rats were received NAC orally by gastric tube at a dose of 400mg/kg every other day and (DOX) i.p. at a dose of 5mg/kg every week for 28 days.

- Group F: Concurrent treatment (NAC2 + DOX) Rats were received NAC orally by gastric tube at a dose of 800mg/kg every other day and DOX i.p. at a dose of 5 mg/kg for 28 days.

At the end of the study, animals were anesthetized by urethane (1.2 g/kg) (*Cocchetto and Bjornsoon, 1983*), and sacrificed, then blood samples were collected and animals were dissected to expose the heart.

IV. Methods

A. Samples collection, preparation and preservation

Blood samples (4ml) from each rat were withdrawn from the retro-orbital venous plexus; each sample was divided into two tubes. (2ml) inside plan tube (no anticoagulant) for

preparation of serum and (2ml) inside heparinized tube (2ml) for preparation of plasma and erythrocyte lysate.

These samples prepared in Metabolic and Genetic disorders Unit. Faculty of Medicine. Assiut University as follow: -

1. **Serum preparation:** the samples in plan tubes allowed to clot for 30 min at 25°C, and then centrifuged at 2000 rpm for 20 min. Then pipette off the top yellow serum layer without disturbing the white buffy layer and preserved at - 20°C in Clinical Toxicology laboratory to the time of assay. Serum is used for estimation of cardiac enzymes (LDH, CK-MB, and CTnI).

2. **Plasma and Erythrocyte lysate preparation:** the samples in heparinized tube centrifuged at 3000 rpm for 20 min then pipette off the yellow plasma layer in tubes and preserved at -20°C to the time of assay. Plasma samples were used for estimation of MDA and GSH levels.

After withdrawal of plasma, the cells were washed once with ten volumes of cold saline. Then lyse the red cell pellets by adding four volumes of cold deionized water to the estimated pellet volume. Remove the red cell stroma by centrifuging at (4000) rpm for 10 min. The resulting clarified supernate (**Erythrocyte lysate**) was collected and preserved at - 20°C in Clinical Toxicology laboratory to the time of assay. **Erythrocyte lysate** is used for estimation of GSH-Px levels.

B. Biochemical analysis

1) Cardiac enzymes assessment

- LDH (lactate dehydrogenase enzyme) level in the serum of male albino rats was estimated by kinetic ultraviolet method using commercial available kits. according to manufacturer instructions.

- CK-MB (creatin kinase MB) level in the serum of male albino rats was estimated by kinetic ultraviolet method using commercial available kits according to manufacturer instructions (VITRO SCIENT) Germany.

- Troponin-I (CTn-I) level in serum of male albino rats was estimated by using commercial available Troponin I enzyme immunoassay test kits according to manufacturer instructions.

2) Oxidative stress markers assessment

- Lipid peroxide MDA (Malondialdehyde) level in plasma of male albino rats was estimated by using colorimetric method Lipid peroxide (Malondialdehyde) test kits. It was determined according to the method of (Sato *K et al.*, 1978).

- Glutathione reduced (GSH) level in plasma of male albino rats was estimated by using colorimetric method using test kits. It was determined according to the method of (Beutler and Kelly, 1963).

- Glutathione peroxidase (GSH-Px) level in erythrocyte lysate of male albino rats was estimated by using colorimetric method using test kits. It was determined according to the method of (Paglia and Valentine, 1967).

C. Histopathological studies

Autopsy sections were taken from the hearts of rats in different groups and fixed in 10% neutral buffered formalin for 24 h. washing was done with tap water, and then dehydration was carried out using serial dilutions of alcohol (methyl, ethyl, and absolute ethyl). Specimens were cleared in xylene and embedded in paraffin at 56°C in a hot air oven for 24 h. Paraffin wax tissue blocks were prepared for sectioning at 5- μ m thickness by a sledge microtome. The obtained tissue sections were collected on glass slides, deparaffinized, stained with hematoxylin, and eosin, and then examination was done through the light electric microscope (Banchroft *et al.*, 1996).

D. Statistical analysis of data

Study data were analyzed using IBM_SPSS. Statistical package for social sciences Ver. 23. (Standard version copyright © SPSS Inc., 2011-2012. NY, USA. 2012). Kruskal-Wallis test was used as the data were abnormally distributed by using test of normality, then data were analyzed by Mann-Whitney U comparison test amongst different groups.

Results

1. Biochemical results.

a) Changes in serum LDH level

The serum level of LDH of the DOX- treated group showed a significant increase (P .

< 0.05) by 70.9% in comparison to the negative group (A). The serum level of LDH of (NAC pre-treated, NAC1+DOX & NAC2+DOX) groups showed a significant decrease ($P. < 0.05$) by 20.3%, 40.1%, and 8.5% respectively when compared to the DOX-treated group. While the LDH level of groups (NAC1+DOX & NAC2+DOX) showed insignificant change ($P.>0.05$) when compared to NAC pre-treated group and that of the group (NAC2+DOX) showed insignificant change ($P. > 0.05$) when compared to group (NAC1+DOX) (as shown in Table 1&2) (Fig. 1)

b) Changes in serum CK-MB level

The serum level of CK-MB of the DOX- treated group showed a significant increase ($P. < 0.05$) when compared to the negative group (A). The levels of serum CK-MB of groups (NAC pre-treated, NAC1+DOX & NAC2+DOX) showed a significant decrease ($P.< 0.05$) when compared to the DOX-treated group, Also, the CK-MB level of groups (NAC1+DOX & NAC2+DOX) showed insignificant change ($P. > 0.05$) when compared to NAC pre-treated group and that of a group (NAC2 + DOX) showed insignificant change ($P.>0.05$) when compared to (NAC1+DOX) group (as shown in Table 1&2) (Fig. 1)

c) Changes in serum cardiac troponin I level

The serum level of CTn-I of DOX- treated group showed a significant increase ($P.< 0.05$) when compared to the negative group (A). The levels of serum CTn-I of groups (NAC pre-treated, NAC1+DOX & NAC2+DOX) showed a significant decrease ($P. < 0.05$) when compared to the DOX-treated group while the serum levels of groups (NAC1+DOX & NAC2+DOX) showed insignificant change ($P. > 0.05$) when compared to the Pre-treated group. Also, the serum CTn-I level of the group (NAC2+DOX) showed insignificant change ($P. > 0.05$) when compared to (NAC1+DOX) group (as shown in Table 1&2) (Fig. 1)

d) Changes in plasma MDA levels

The plasma level of malondialdehyde (MDA) of DOX-treated showed a significant increase ($P. < 0.05$) by 238.4% when compared to the negative group (A). The levels of plasma MDA of NAC pre-treated showed a significant decrease ($P. < 0.05$) by 77.7 when compared to the DOX-treated group

while the levels of groups (NAC1+DOX & NAC2+DOX) showed insignificant change ($P.> 0.05$) when compared to the DOX-treated group. In addition, the MDA levels of the group (NAC1+DOX) showed a significant increase ($P=0.001$) when compared to NAC pre-treated group, and that of (NAC2+DOX) group showed insignificant change ($P.> 0.05$) in comparison to (NAC1+DOX) **as shown in Table 3&4) (Fig. 2)**

e) Changes in plasma GSH levels

The plasma level of GSH of the DOX- treated group showed a significant decrease ($P. < 0.05$) by 46.4% in comparison to the normal group (A). The plasma level of GSH of groups (NAC pretreated, NAC1+DOX & NAC2+DOX) showed a significant increase ($P. < 0.05$) by 64%, 91.8%, and 93.32% when compared to group C (DOX treated). While the plasma levels of groups (NAC1+DOX & NAC2+DOX) showed a significant increase ($P. < 0.05$) by 17% and 17.8% respectively when compared to the (NAC pre-treated) group, but that of the group (NAC2+DOX) showed insignificant change ($P.> 0.05$) when compared to (NAC1+DOX) group **as shown in Table 3&4) (Fig. 2).**

f) Changes in erythrocyte lysate GSH-Px levels

The GSH-Px level in the erythrocyte lysate solution of the DOX-treated group showed a significant decrease ($P. < 0.05$) by 39.4% when compared to the negative group (A). The level of erythrocyte lysate GSH-Px of groups (NAC pretreated, NAC1+DOX) showed a significant increase ($P. < 0.05$) by 23.7% and 72.06% when compared to the DOX-treated group while the erythrocyte lysate levels of groups (NAC1+DOX & NAC2+DOX) showed insignificant change ($P.> 0.05$) when compared to the NAC pre-treated group. The plasma level of (NAC2+DOX) group showed insignificant change ($P.> 0.05$) in comparison to (NAC1+DOX) group **as**

shown in Table 3&4) (Fig. 2)

2. Histopathological results (shown in figure 3)

Examination of cardiac sections of the negative control group showed normal architecture of cardiac muscles (Fig 3 A). Cardiac sections of NAC treated group showed normal findings (Fig. 3 B). Sections from cardiac muscle tissues in DOX-treated group showed histopathological changes was recognized by disrupted cardiac muscle fibers and foci of degeneration of the myocardium (Fig. 3 C). Sections of rat cardiac muscle tissue, which received (NAC pre-treated) & (NAC1+ DOX) group, showed small foci hemorrhage and mild disruption of cardiac muscles (Fig. 3 D&E). Sections from rat hearts of NAC2+DOX treated group (showed restoration of most of the normal cardiac tissue architecture and cardiac muscles showing no significant pathological changes (Fig. 3 F).

Table (1) The effects of i.p. DOX and oral administration of NAC on serum levels of cardiac markers LDH, CK-MB and CTn-I in the six studied groups.

Each value represents the median value minus interquartile range.

Group Variable	A	B	C	D	E	F	p-value by
	Median(IQR)						
LDH unit (U/L)	981(470-2244.25)	1165(1089.25-2040)	1677.5(1435-1834)	1336.5(914-1771.5)	1004(843-1811)	1535(1210.75-1971.25)	0.004**
CK-MB (U/L)	136(111.45-229.5)	129(80.45-203)	261(123.88-367.5)	163(28-178.5)	143 (105-234)	141(24.98-276)	0.042*
CTn-I (ng/ml)	0.3(0.17-0.64)	0.37(0.21-0.46)	0.64(0.27-0.84)	0.53(0.44-0.79)	0.48(0.27-0.48)	0.52(0.37-0.99)	0.038*

Statistical analysis was carried out by Kruskal-Wallis test among all groups and shows statistically significant differences in cardiac enzymes between groups.

* Statistically significant difference ($p. <0.05$)** Highly statistically significant difference ($p. <0.01$).**Table (2): The significance changes in cardiac markers assessment.**

Group Variable	P-value										
	B VersusA	C VersusA	D VersusA	E VersusA	VersusA	D VersusC	E VersusC	F VersusC	E VersusD	F VersusD	F VersusE
LDH	0.387	0.040*	0.022*	0.005**	0.036*	0.035*	0.012*	0.004**	0.671	0.419	0.701
CK-MB	0.283	0.045*	0.274	0.868	0.369	0.001**	0.011*	0.034*	0.353	0.804	0.494
CTn-I	0.400	0.007**	0.022*	0.552	0.018*	0.009**	0.003**	0.001**	0.452	0.499	0.654

Statistical analysis was done using Mann-Whitney U multiple comparison test.

* Statistically significant difference ($p. <0.05$)** Highly statistically significant difference ($p. <0.01$).

DOX (Doxorubicin), **NAC** (N-Acetylcystiene), **i.p** (Intraperitoneal), **LDH** (Lactate dehydrogenase enzyme), **CK-MB** (creatin kinase isoenzyme in blood), **CTn-I** (cardiac troponin – I).

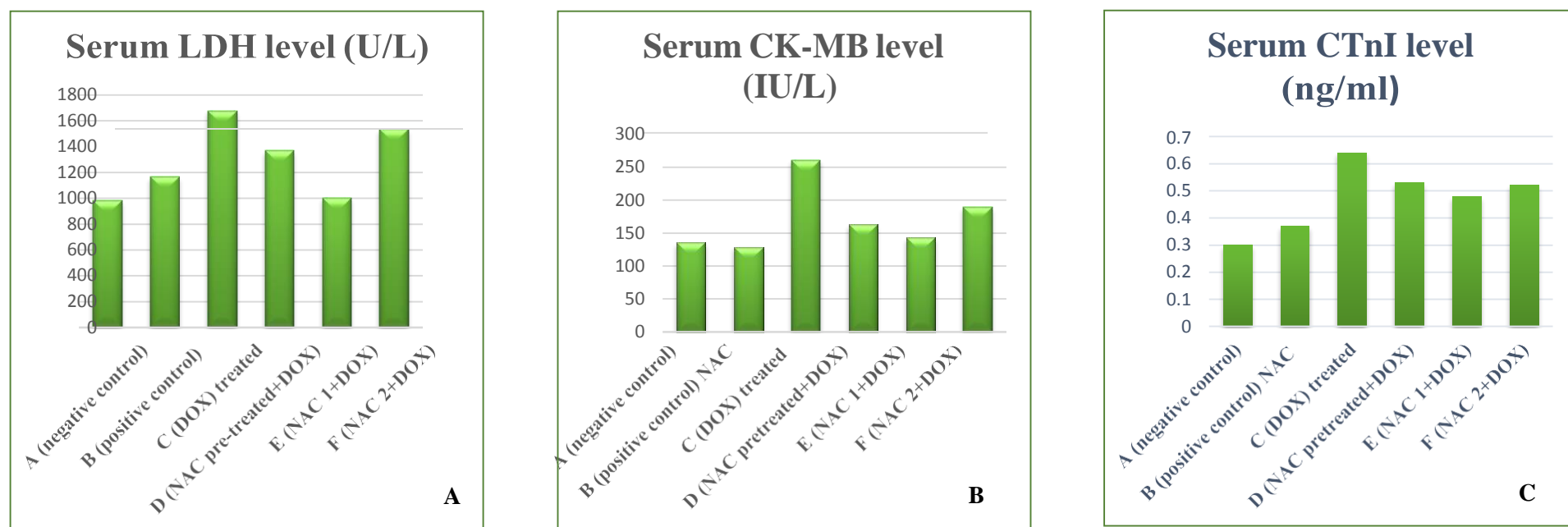


Figure: (1) (A, B & C) Effect of oral administration of (NAC) on the serum level of (LDH (A) , CK-MB (B), and CTn-I (C)) in doxorubicin-induced cardiac toxicity in rats. Each value represents the median \pm IQR. Data were analyzed by Kruskal-Wallis test followed by MannWhitney U comparison test amongst different groups.

Table (3) The effects of i.p. DOX and oral administration of NAC on serum levels of oxidative stress markers MDA (Malondialdehyde), GSH, and GSH-Px in six studied groups. Each value represents the median value and interquartile range.

Variable \ Group	A	B	C	D	E	F	p-valueby
	Median(IQR)						
MDA (nmol/ml)	80.88(56.75-150)	87.5(51.44-111.81)	273.75(111.25-712.5)	61.13(25-107.88)	92.5 (87.5-163)	180.25(32.5-352.5)	0.012*
GSH (mg/dl)	93.33(84.99-103.32)	95.66(76.66-100.99)	50(44-52.99)	82(79.99-88.66)	95.99(95.32-97.32)	96.66(89.16-101.82)	0.000**
GSH-Px (Mu/L)	37.2(13.89-26.87)	39.91(5.74-29.16)	22.55(39.98-54.44)	27.9(5.23-23.89)	38.8(12.84-30.14)	41.7(6.76-65.9)	0.277

Statistical analysis was carried out by Kruskal-Wallis test among all groups and shows statistically significant differences regarding MDA&GSH between groups.

* Statistically significant difference ($p. <0.05$)

** Highly statistically significant difference ($p. <0.01$).

Table (4): The significance changes in oxidative stress parameters assessment.

Variable \ Group	P-value										
	B VersusA	C VersusA	D VersusA	E VersusA	F VersusA	D VersusC	E VersusC	F VersusC	E VersusD	F VersusD	F VersusE
MDA	0.401	0.004**	0.967	0.006**	0.600	0.001**	0.050	0.394	0.001**	0.571	0.094
GSH	0.569	0.000**	0.012*	0.416	0.866	0.000**	0.000**	0.000**	0.001**	0.007**	0.514
GSH-Px	0.312	0.001**	0.824	0.969	0.123	0.003**	0.001**	0.896	0.855	0.079	0.119

Statistical analysis was done using Mann-Whitney U multiple comparison test.

* Statistically significant difference ($p. <0.05$).

** Highly statistically significant difference ($p. <0.01$).

DOX (Doxorubicin) , **NAC** (N-Acetylcystiene), **i.p** (Intraperitoneal), **MDA** (Malondialdehyde), **GSH** (Reduced glutathione), **GSH-Px** (Glutathione peroxidase enzyme).

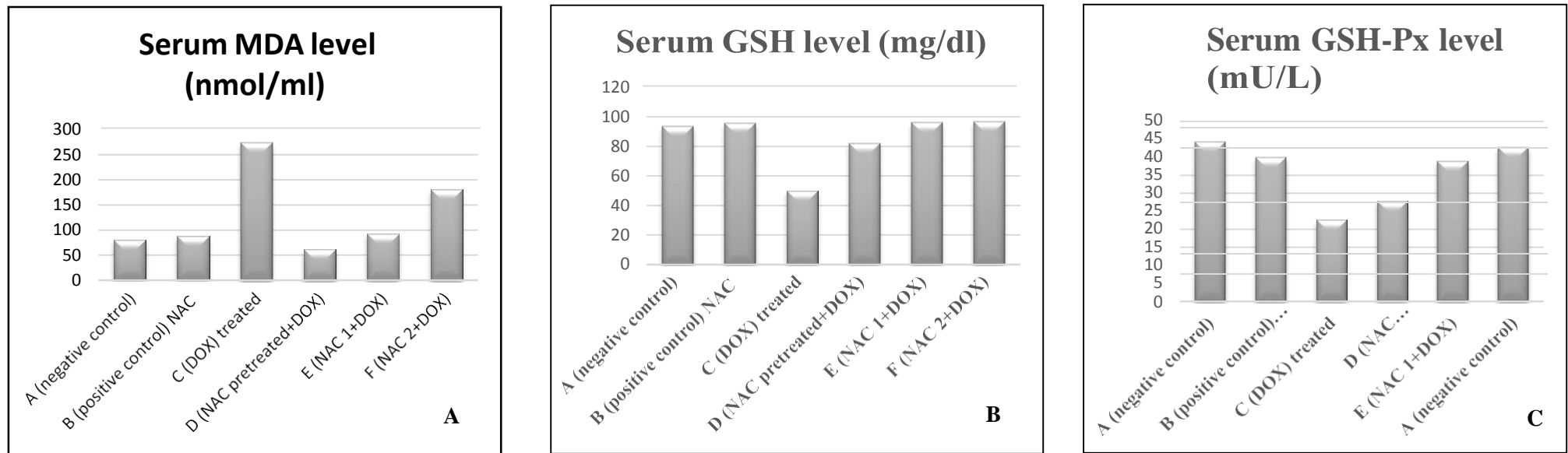


Figure: (2) (A, B &C) Effect of oral administration of (NAC) on the plasma level of (MDA (A), GSH (B) and RBCs lysate level of (GSH-PX) (C) in doxorubicin-induced oxidative stress in rats. Each value represents the median \pm IQR. Data were analyzed by Kruskal-Wallis test followed by Mann Whitney U comparison test amongst different groups.

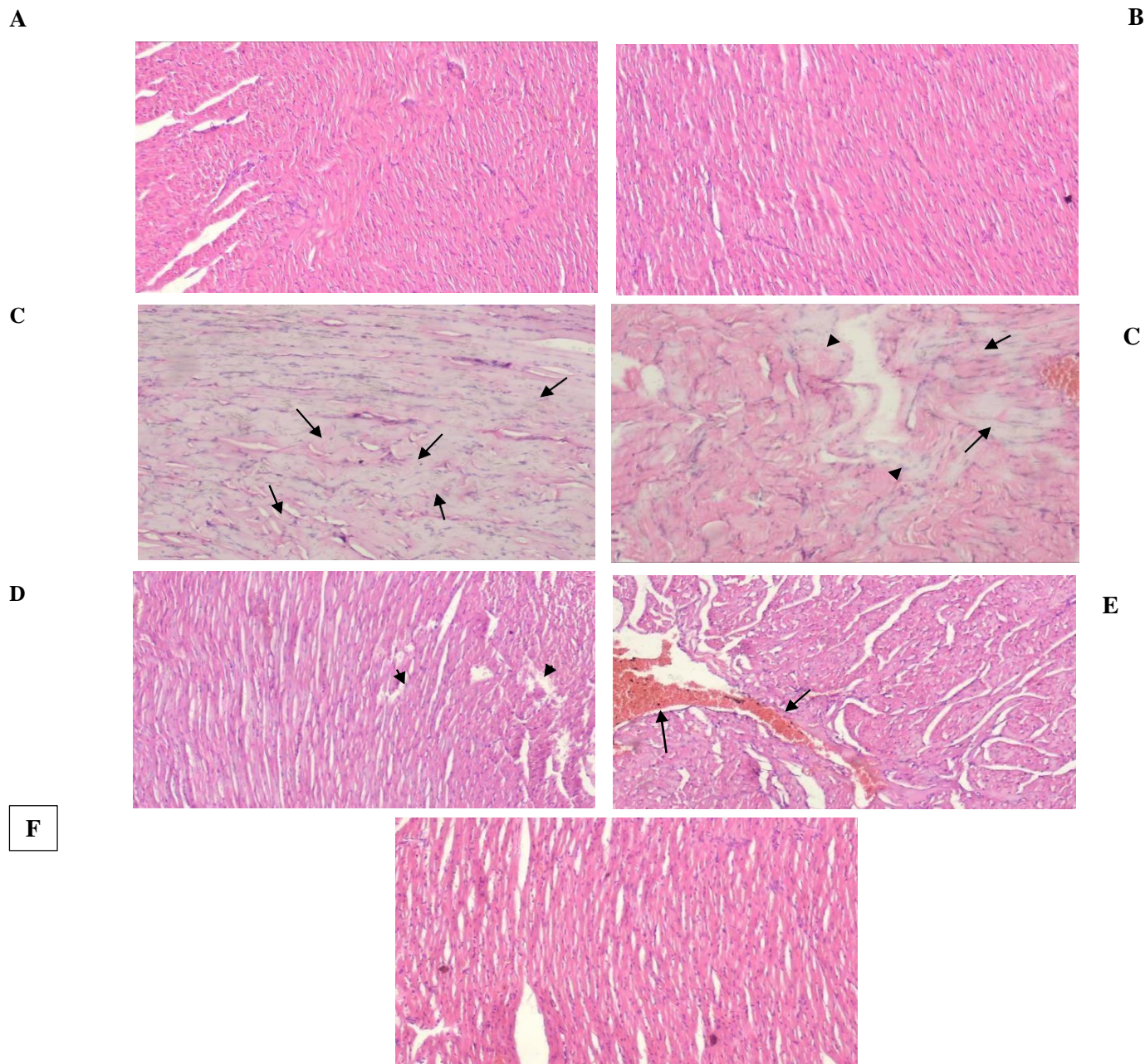


Figure: (3) A Photomicrographs of the cardiac tissue showing effects of oral administration of N-acetyl cysteine in doxorubicin- induced cardiotoxicity in rats. (A) cardiac tissue of the control negative group showing normal cardiac architecture (H&E x200). (B) cardiac tissue of NAC only treated group showing normal cardiac muscle architecture (H&E x200). (C) cardiac tissue of the DOX-treated group showing disrupted cardiac muscle fibers (left one-arrows) and disrupted cardiac muscle fibers & foci of degeneration of the myocardium (right one-arrows & arrow heads). Sections of rat heart from (D) which received (NAC pre-treated) &(E) group which received NAC1+ DOX, cardiac muscles showing mild disruption of cardiac muscles (arrow heads) and small foci hemorrhage (arrows). Sections from rat hearts of group (F) which received NAC2+DOX showed restoration of most of the normal cardiac muscle tissue architecture and cardiac muscles showing no significant pathological changes.

Discussion:

Doxorubicin (DOX) is an anthracycline antibiotic and one of the most powerful and widely used chemotherapeutic agents for different types of solid and hematological tumors. Unfortunately, clinical application of this drug leads to severe cardiotoxicity (Yu *et al.*, 2018).

In the present study, the protective and ameliorative effects of N-acetylcysteine (NAC) against (DOX) induced cardiac toxicity was investigated in male albino rats. The rats were divided into six groups ten rats each.

The present study showed a significant increase in serum levels of LDH, CK-MB & CTn-I levels ($p < 0.05$) by 70.9%, 91.1%, and 113.3 respectively in DOX treated group when compared to negative control group.

The most severe side effect of DOX is dose-dependent cardiotoxicity, which takes place through inducing oxidative stress apoptosis (Abushouk *et al.*, 2017). Also, the cellular mechanisms underlying DOX-induced cardiotoxicity include free-radical damage to cardiac myocytes, leading to mitochondrial injury and subsequent death of myocytes (Nonaka *et al.*, 2017).

Elevations in baseline high-sensitivity cardiac troponin T (hscTn-T) levels are suggestive of an oncology subgroup at high risk of developing cardiac complications from their chemotherapy. (Blaes *et al.*, 2015). in agreement with the present results recently, Olorundare *et al.* (2020) results revealed that serum cardiac troponin I and LDH were significantly elevated by the DOX treatment.

The results obtained in Abd El-Gawad and El-Sawalhi, (2003) study agree with that obtained in this current study when DOX was given in a dose of (2.5 mg/kg/BW) twice per week for two weeks, he found that cardiotoxicity was manifested by a

marked increase in serum LDH and CPK in addition to the sharp increase in MDA reaching eightfold the basal level.

In Saad *et al.* (2004) DOX was given in a dose of (5mg/kg) twice per week for two weeks, the induced cardiotoxicity was manifested by abnormal biochemical changes including marked increases in serum (CK-MB), (LDH), glutathione peroxidase (GSH-Px).

The current study results agree with that of Alkreathy *et al.* (2010) study, where a single dose of DOX (25mg/kg) caused increased both serum cardiac enzymes LDH and CPK activities and a significant increase in plasma level of MDA.

Similar findings were present in Al-Harathi *et al.*, (2014), the tested dose of DOX (20 mg/kg) caused a significant increase in the serum activities of the cardiac enzymes lactate dehydrogenase (LDH), creatine phosphokinase (CPK), and the level of malondialdehyde (MDA) in the heart tissue. In addition, there was a significant decrease in the glutathione level in the heart tissue.

The current study results agree with those gained in El-Sayed, *et al.* (2016) study where the tested dose of DOX was given (10 mg/kg) i.v. injection once in 16 days, it induced marked and significant increase in serum levels of LDH, CK-MB & CTn-I, these changes were attributed to DOX induced cardiac damage.

The present study results agree with that obtained from Bai *et al.*, (2019) Who investigated the cardio-toxic effects of DOX in a dose of (5 mg/kg) I.P injection once per week for four weeks and found significant increase in CTn-I level when compared to control.

DOX-induced cytotoxic effects on the heart could be clarified by free radicals created by DOX and interacts with the mitochondrial and endoplasmic reticulum membranes leading to their

degeneration and consequent cell apoptosis (*Zhan et al., 2015*).

The current study showed that there was significant decrease in serum levels of LDH, CK-MB and CTn-I in NAC pre-treated group, (NAC1+DOX) & (NAC2+DOX) by (20.3%, 40.1, and 8.5%) (37.5%, 45.5, and 45.6) (17.2%, 25%, and 18.75%) respectively when compared to DOX-treated group and this indicates that

NAC therapy either pre-treatment or concurrently administered with DOX can ameliorate and suppresses DOX-induced elevations of cardiac markers.

The serum levels of LDH, CK-MB and CTn-I in groups (NAC1+DOX & NAC2+DOX) showed insignificant change when compared to (NAC pre-treated) group, we infer that no difference in effect between NAC concurrent treatment and pre-treatment with NAC. The serum levels of LDH, CK-MB and CTn-I of (NAC2+DOX) group showed insignificant change when compared to group (NAC1+DOX), that means no difference noticeable between protective effect of NAC with different doses.

NAC prevented the negative inotropic effect produced by DOX on isolated rat atria. A good relationship exists between the cardio- protective effects of NAC and its ability to enhance the non-protein sulfhydryl group content of the myocardium (*Villani et al., 1990*).

The results of the current study agree with *Pereira et al., (2019)* who concluded that N-acetylcysteine play a protective role in cardiac surgery it was safely administered to patients in all included studies in this review. Cardiac markers LDH, CK-MB, and CTn-I levels were significantly improved in those patients with marked restoration of GSH cardiac tissue stores

Reddy et al. (2011) stated that the use of

substances with antioxidant properties has been proven effective at protecting the cardiac muscle against damage caused by reactive oxygen species (ROS) generation. In this sense, several studies (*Arica et al., 2013; Al-Harathi et al., 2014; Abushouk et al., 2017*) have shown that NAC can reduce the effects caused by DOX. They reported that NAC was able to restore the anti- and pro-oxidant balance of the cardiac muscle and prevent the harmful effects of doxorubicin treatment.

NAC largely reduced CK-MB release in diabetic rats. NAC alone reasonably decreased cardiac troponin I levels in diabetic rats (*Lin et al., 2016*).

The present study results revealed that sections from cardiac muscles of DOX-treated group showed evidence of toxic effects demonstrated as areas of disrupted cardiac muscle fibers with foci of degeneration. However, with NAC therapy, cardiac muscles of groups (NAC pretreated & NAC1+DOX) exhibit small foci hemorrhage and mild disruption of cardiac muscles. Whereas, Cardiac muscles of group (NAC2 + DOX) showed no significant pathological changes. The pathological changes occur after administration of DOX were in concordance with previous studies as in study by *Swamy and his colleagues (2012)*. In their study DOX was given in dose of 2.5mg/kg/BW i.p three times per week for two weeks. Results revealed that DOX-treated group showed loss of myofibrils and vacuolization of the cytoplasm were observed.

Shivakumar et al. (2012) results were in agreement with current study. Examination of sections from the heart in male rats treated with DOX (2 mg/kg/BW) once per week for four weeks showed inter-fibrillar hemorrhages, congestion, and focal areas of disrupted cardiac muscle fibers. DOX produced necrosis, hemorrhages and leukocyte infiltration in the myocardium. The injury to the

myocardium can be explained by oxidative stress induced by the reactive intermediates doxorubicin semiquinone formed from doxorubicin. The anthracyclines are reported to form semiquinone radical intermediates, which react with molecular oxygen to form reactive oxygen species that interact with macromolecules of the cells to induce tissue damage.

The present study results agree with that obtained from (*Farshid et al., 2014*). Who investigated the protective effects of NAC against DOX –induced cardiotoxicity, NAC administered as 40mg/kg/BW I.P; doxorubicin was given 4mg/kg/BW for four weeks. Results showed reversal of serum elevated LDH, CPK and MDA induced by DOX. Also cardiac sections showed partial reduction in leucocyte infiltration and necrosis. Also, *Arica et al. (2013)* who studied the effect of NAC protection against DOX-induced cardiotoxicity. NAC was given in a dose of 200mg/kg/BW once every day for five days and DOX was given as 20 mg/kg/BW as a single dose once. Results showed that preservation of the general architecture of cardiac muscle tissue. However, edema, disorganization, and myofibril loss was minimal than DOX-treated group. This could be explained by the antioxidant activity of NAC and this is confirmed by modulation of cardiac enzyme back to normal in NAC treated groups in comparison to DOX-treated group. Moreover, NAC showed a protective role in the cardiac tissue of rats submitted to hemorrhagic shock, mainly in lessening oxidative stress and histologic injury (*Oliveira Filho et al., 2015*).

Lu et al. (2016) study that investigated Doxorubicin-induced myocardial damage (2.5 mg/kg/BW) i.p. injection once per week for six weeks Results revealed serious myocardial damage characterized by disorganization of myo-fibrillar arrays, interstitial fibrosis, massive cardiomyocyte

loss, cytoplasmic vacuolization, eosinophilic degeneration and forceful infiltration of neutrophil granulocytes.

In agreement with these results, *Mostafa and Raafat, (2019)* found that in Wister adult male albino rats that received NAC 250mg/kg/BW by nasogastric tube every day. DOX (2.5mg/kg/BW) was given three times a week for two weeks. Cardiac stained sections revealed that the cardiac muscle fibers showed improvement in pathological findings after administration of NAC. There was improvement in vacuolations and fibrosis. NAC can attenuate the effects caused by DOX and able to restore the anti- and pro-oxidant balance of the cardiac muscle and prevent the injurious effects of DOX treatment. This may be explained by enriching glutathione (GSH), an important enzyme of the cellular antioxidant system that is able to stimulate and sustain its intracellular levels, which detoxify reactive oxygen species.

On the other hand, (*Shi et al., 2009*) who studied the ability of NACA to protect cardiomyocytes in tissue culture from DOX-induced toxicity. N-acetylcysteine amide (NACA), a structural analogue of NAC, was synthesized and evaluated in certain in vivo and in vitro models. They found that although NACA was able to provide oxidative relief; it only had minimal protective effect on DOX-induced cell death.

To summarize, our results indicate that NAC induces ameliorative and protective effects against DOX-induced cardiotoxicity as NAC restores the elevated cardiac enzymes in NAC treated groups (pre-treated and concurrent) in comparison to DOX-treated group. These results were confirmed by the histopathological findings as NAC was able to restore cardiac muscle architecture to near normal except some muscle disruption and few foci of hemorrhage in few areas in NAC pre-

treated and NAC1+DOX groups. Furthermore, NAC2+DOX group sections showed no pathological abnormalities. This can be explained by doubling the dose of NAC can restore histological changes to normal.

The present study showed a significant increase in serum level of MDA by 238.4% and a significant decrease in serum GSH & GSH-Px levels by 46.4% and 39.4% in DOX treated group when compared to control groups.

These results can be explained by DOX undergoes antioxidant redox cycling resulting in the production of ROS; DOX generates semiquinone radicals, which in turn react with molecular oxygen and provide other ROS at an early stage after administration (*Bulucu et al., 2010*).

The current study agrees with most studies that had recorded elevation of MDA in heart tissue after acute and chronic application of DOX (*Mokni et al., 2012; Ammar et al., 2013*).

Frijhoff et al. (2015) stated that GSH is an intracellular non-enzymatic antioxidant and one of the most important scavengers of free radicals. In addition, it is a co-factor of many detoxifying enzymes against oxidative stress as GSH-Px and glutathione reductase (GR).

The current study agree with results obtained from *Kwatra et al. (2016)* study in which DOX was given in a dose of (15 mg/kg) I.P injection at 10th day, results revealed that Doxorubicin-induced cardiotoxicity confirmed by significant increase in MDA level, significant decrease in GSH level.

The present study agrees with *Rashid et al. (2013); Kwatra et al. (2016) and Song et al. (2019)* studies that DOX administration significantly decreased the levels of antioxidant enzymes, namely, superoxide dismutase (SOD), GSH-Px,

GR, and catalase (CAT) in rats in response to free radical formation, supporting the serious role of oxidative stress in DOX hepatotoxicity.

Lipid peroxidation includes oxidation of lipids, yields an aldehyde (MDA). Administration of (DOX) was closely associated with lipid peroxidation which is attributed to increase in free radical formation, thereby, suggesting a state of oxidative injury as reported previously in the heart and liver of animals after Dox administration (*Rashid et al., 2013; Rehman et al., 2014; Kuzu et al., 2019*).

The current study results agree with *Kuzu et al. 2019* who investigated the DOX induced effects on oxidative status by using DOX in a dose of (40mg/kg/BW) I.p. injection on the 8th day and the study continued for 10 days. The results showed a significant increase in MDA levels and a significant decrease in GSH and GSH-Px levels, this may be due to the high dose (40 mg/kg) indicating the highly toxic profile of DOX even if there is short duration (48 hours) interval between the dose and samples taken. Current results agreement with aforementioned studies proves DOX-induced toxicity against the normal oxidative status.

Lipid peroxidation is the hallmark of oxidative stress. It results in increase of fibrogenic cytokines by stimulating the formation of collagen and liver stellate cells. DOX administration results in a substantial increase in the lipid peroxidation. Therefore, leading to marked increase of ROS as well as exhaustion of cellular antioxidant defense system markers including GSH, GSSG, CAT, SOD, GSH-Px, GR, and H₂O₂ levels (*Afsar et al., 2019*). The results of the presenting study agree with that obtained from *Walaa et al. (2019)* study, DOX was given in a dose of (4mg/kg) for four weeks, there was significant increase in MDA level and a massive decrease in the brain GSH & GSH-Px levels in the DOX-treated group compared to the control group.

Current obtained results agree with *Wali et al. (2020)* in that there was a significant increase in MDA (a well-known biomarker of oxidative stress & lipid peroxidation) level, also a significant decrease in both GSH & GSH-Px activity when compared to control group.

Results of *Wali et al. (2020)* study who investigated the toxic effects of DOX on the liver. DOX was given in a dose of (20 mg/kg) in the 20th day of 21-day study, it showed that ROS were significantly higher in (Dox-treated group) when compared with the control group. Revealing that (DOX) increases oxidative stress by instigating ROS & RNS that play role in number of cellular mechanisms like redox cycling of quinone moiety of doxorubicin and disrupt iron homeostasis.

The present study showed insignificant change in plasma MDA levels in groups (NAC1+DOX & NAC2+DOX) when compared to (DOX treated) group. There is a significant decrease in plasma MDA level of (NAC pre-treated) group by 77.7% when compared to DOX treated, and this indicates that effect of NAC pre-treatment has a better result to decrease lipid peroxidation than concurrent treatment.

Plasma GSH levels in groups (NAC pretreated, NAC1+DOX & NAC2+DOX) showed significant increase by 64%, 91.8%, and 93.32% respectively when compared to (DOX treated) group. Furthermore, a significant increase in plasma GSH levels of groups (NAC1+DOX & NAC2+DOX) when compared to (NAC pretreated) group. This reflects effects of concurrent more than NAC pre-treatment, there is no statistically significant change in GSH level in group (NAC2+DOX) when compared to group (NAC1+DOX), so no value added by increasing the dose of NAC to ameliorate GSH level.

Erythrolysate level GSH-Px levels results showed significant increase in groups (NAC pretreated & NAC1+DOX) by 23.7% and 72.06%

respectively when compared to DOX treated. While Erythrolysate GSH-Px levels showed insignificant change in groups (NAC1+DOX & NAC2+DOX) when compared to NAC pretreated, and insignificant change in group (NAC2+DOX) when compared to group (NAC1+DOX), so these results refers to the NAC effect to restore GSH-Px activity after DOX induced oxidative changes without significant restorative effects differences between NAC pre-treatment or concurrent treatment options.

The present study agrees with *Koçkar et al. (2010)* who investigated NAC modulation effect on DOX-induced oxidative stress in rat liver. DOX was given in a dose (2.5 mg/kg/BW) once and NAC (10 mg/kg/BW) every day for 10 days (experiment duration). Results showed serum GSH level significantly increased in the (DOX+NAC) group than in control and DOX group. GSH-Px levels showed insignificant changes in the three groups by DOX and NAC administrations. In conclusion, N-acetylcysteine induced modulator effects on the doxorubicin-induced hepatotoxicity by inhibiting free radical production and supporting the antioxidant vitamin levels.

Sathish et al., (2011) showed that Post-treatment with NAC 50 mg/kg daily for 7 days effectively prevent the elevation in oxidative stress marker enzymes and LPO, and restoring the activities of both the enzymic (SOD, CAT and GPx) and non-enzymic (GSH, Vit.C and Vit.E) antioxidants and membrane bound ATPases towards normal.

Walaa et al. (2019) found that administration of NAC produced a statistically significant increase in GSH and GPx levels. The uniqueness of NAC is most probably due to its serving as a precursor of L-cysteine for GSH synthesis (*Samuni et al., 2013*).

The present study results agree with *Mansour and Hasan (2015)* study as NAC given in

(200mg/kg) i.v for five days then a single dose of cyclophosphamide given after 1hour of last NAC dose. After one day samples were taken, the results showed that marked and significant decrease in MDA level, also significant increase in both GSH & GSH Px.

The normalization of MDA following NAC treatment is very likely due to its anti- peroxidative properties (*Zafarullah et al., 2003*), as the presence of acetyl and sulfhydryl groups makes NAC an effective inhibitor of lipid peroxidation (*Dhouib et al., 2015*).

Conclusion:

- DOX administration in cumulative dose 20mg/kg/BW induced cardiac toxicity at biochemical and histopathological levels.
- NAC treatment did not induce any observed toxic effects in any dose used in our study.
- NAC induces ameliorative and protective effects against DOX-induced cardiotoxicity as NAC restores the elevated cardiac enzymes in NAC treated groups (pre-treated and concurrent) in comparison to DOX- treated group. These results was confirmed by NAC induced effects in restoring cardiac muscle architecture to near normal except some muscle disruption and few foci of hemorrhage in few areas in NAC pre-treated and NAC1+DOX groups.
- Furthermore, NAC2+DOX group sections shows no pathological changes in cardiac tissues. This can be explained by adding more protective effect of doubling the dose of NAC.

References:

- 1) **Abd El-Gawad HM and El-Sawalhi MM. (2003):** Nitric oxide and oxidative stress in brain and heart of normal rats treated with doxorubicin: role of aminoguanidine. *J Biochemical and Molecular Toxicology*;18(2):69-77.
- 2) **Abushouk AI, Ismail A, Salem AMA, Afifi AM, and Abdel-Daim MM. (2017):** Cardioprotective mechanisms of phytochemicals

against doxorubicin- induced cardiotoxicity. *Biomedical Pharmacotherapy*; 90:935-946.

- 3) **Afsar, T, Razak S, and Almajwal A. (2019):** Effect of *Acacia hydasypica* R. Parker extract on lipid peroxidation, antioxidant status, liver function test and histopathology in Doxorubicin treated rats. *Lipids Health Dis.*, 18, 126.
- 4) **Al-Harathi SE, Alarabi OM, Ramadan WS, Alaama MN, Al-Kreathy HM, Damanhoury ZA, Khan LM, and Osman AM. (2014):** Amelioration of doxorubicin-induced cardiotoxicity by resveratrol. *Mol Med Rep*; 10(3):1455- 1460.
- 5) **Alkreathy H, Damanhoury ZA, Ahmed N, Slevin M, Ali SS, and Osman AM. (2010):** Aged garlic extract protects against doxorubicin-induced in rats. *Food and Chemical Toxicology* 48 (3):951-956.
- 6) **Ammar ESM, Said SA, El-Damarawy SL, and Suddek GM. (2013):** Cardioprotective effect of grape-seed proanthocyanidins on doxorubicin-induced cardiac toxicity in rats. *Pharmaceutical Biology*, 51, 339–344.
- 7) **Arica V, Demir IH, and Tutanc M. (2013):** N-acetylcysteine prevents doxorubicin-induced cardiotoxicity in rats. *Human and Experimental Toxicology*; 32(6):655-661.
- 8) **Bai, Zhifeng, and Zhijian Wang. (2019)** "Genistein protects against doxorubicin- induced cardiotoxicity through Nrf- 2/HO- 1 signaling in mice model." *Environmental toxicology* 34.5: 645-651.
- 9) **Bancroft J, and Cawood E H. (1996):** Androgens and the menopause; a study of 40–60-year- old women. *Clinical Endocrinology*, 45(5), 577-587.
- 10) **Blaes AH, Rehman A, Vock DM, Luo X, Menge M, Yee D, Missov E, and Duprez D. (2015):** Utility of high-sensitivity cardiac troponin T in patients receiving anthracycline chemotherapy. *Vascular Health Risk Management*;

11:591-594.

11) **Bulucu F, Ocal R, and Karadurmus N. (2010):** Effects of N-acetylcysteine, deferoxamine, and selenium on doxorubicin-induced hepatotoxicity. *Biol ogia Trace Elementa Res*; 132: 184–196.

12) **Cardinale D, Colombo A, Bacchiani G, Tedeschi I, and Meroni CA, Veglia F. (2015):** Early detection of anthracycline cardiotoxicity and improvement with heart failure therapy. *Circulation*;131:1981–1988.

13) **Cocchetto D M, and Bjornsson T D. (1983):** Methods for vascular access and collection of body fluids from the laboratory rat. *Journal of pharmaceutical sciences*, 72(5), 465-492.

14) **Dauletbaev N, Fischer P, Aulbach B, Gross J, Kusche W, Thyroff-Friesinger U, and Bargon J. (2009).** A phase II study on safety and efficacy of high-dose N-acetylcysteine in patients with cystic fibrosis. *European journal of medical research*, 14(8), 352-358.

15) **Dhouib I E, Annabi A, Jrad A, Gharbi N, Lasram MM, and El-Fazaa S. (2015)** “Protective effect of n-acetylcysteine against toxicity on the rat blood after chronic exposure to carbosulfan,” *Recent Advances in Biology and Medicine*, vol. 1, pp. 18–25.

16) **Elbini Dhouib I, Jallouli M, Annabi A, Gharbi N, Elfazaa S, and Lasram M M. (2016):** “A minireview on N- acetylcysteine: An old drug with new approaches,” *Life Sciences*, vol. 151, pp.359–363.

17) **El- Sayed, El- Sayed M., Ahmed M. Mansour, and Mohammed S. and Abdul-Hameed. (2016):** "Thymol and carvacrol prevent doxorubicin- induced cardiotoxicity by abrogation of oxidative stress, inflammation, and apoptosis in rats." *Journal of biochemical and molecular toxicology* 30 (1): 37- 44.

18) **Farshid AA, Tamaddonfard E, and Simaee N. (2014):** Effects of histidine and N-

acetylcysteine on doxorubicin- induced cardiomyopathy in rats. *Cardiovascular Toxicology*; 14(2):153-161.

19) **Frijhoff J, Winyard PG, Zarkovic N, Davies SS, Stocker R, Cheng D, Knight A R, and Ghezzi P. (2015):** Clinical Relevance of Biomarkers of Oxidative Stress. *Antioxidant and Redox Signaling*; 23 (14):1144-1170.

20) **Ho E, Brown A, Barrett P, Morgan RB, King G, Kennedy MJ, and Murphy RT. (2010):** Subclinical anthracycline- and trastuzumab-induced cardiotoxicity in the long-term follow-up of asymptomatic breast cancer survivors: a speckle tracking echocardiographic study. *Heart*; 96:701–707.

21) **Koçkar MC, Nazıroğlu M, Celik O, Tola HT, Bayram D, and Koyu A. (2010):** N-acetylcysteine modulates doxorubicin-induced oxidative stress and antioxidant vitamin concentrations in the liver of rats. *Cell Biochemical Functions*; 28(8):673-677.

22) **Kulkarni J M and Swamy A V. (2015).** Cardioprotective effect of gallic acid against doxorubicin-induced myocardial toxicity in albino rats. *Indian Journal of Health Sciences and Biomedical Research (KLEU)*, 8 (1):28-35.

23) **Kuzu M, Yıldırım S, Kandemir FM, Küçükler S, Çağlayan C, Türk E, and Dörtbudak MB. (2019):** Protective effect of morin on Doxorubicin-induced hepatorenal toxicity in rats. *Chem. Biol. Interact*; 1:89–100.

24) **Kwatra M, Kumar V, Jangra A, Mishra M, Ahmed S, Ghosh P, Vohora D, and Khanam R. (2016):** Ameliorative effect of naringin against doxorubicin-induced acute cardiac toxicity in rats. *Pharmacological Biology*; 54 (4):637-647.

25) **Lin J, Wang T, and Li Y. (2016):** N-Acetylcysteine Restores Sevoflurane Post conditioning Cardio-protection against Myocardial Ischemia Reperfusion Injury in Diabetic Rats. *Journal of Diabetes Research*; 9213034.

- 26) **Lu PP, Ma J, and Liang XP. (2016):** Xinfuli improves cardiac function, histopathological changes, and attenuates cardiomyocyte apoptosis in rats with doxorubicin-induced cardiotoxicity. *Journal of Geriatric Cardiology*; 13(12):968-972.
- 27) **Mansour H H, and Hasan H F. (2015):** Protective effect of N-acetylcysteine on cyclophosphamide-induced cardiotoxicity in rats. *Environmental toxicology and pharmacology*, 40(2):417-422.
- 28) **Mokni M, Hamlaoui-Guesmi S, Amir M, Marzuki L, Limam F, and Aouan E. (2012):** Grape seed and skin extract protects against acute chemotherapy toxicity induced by doxorubicin in rat heart. *Cardiovascular Toxicology*, 12: 158–165.
- 29) **Mostafa H K, and Raafat MH. (2019):** Effect of N-Acetyl Cysteine on Doxorubicin Induced Cardiotoxicity in Adult Male Albino Rat: Histological Study. *Journal of Cytology and Histology* 10 (2): 1000536.
- 30) **Murabito A, Hirsch E, and Ghigo A. (2020):** Mechanisms of Anthracycline- Induced Cardiotoxicity: Is Mitochondrial Dysfunction the Answer? *Frontiers in Cardiovascular Medicine.*; 7.
- 31) **Nonaka M, Kurebayashi N, Murayama T, Sugihara M, Terawaki K, Shiraishi S, Miyano K, Hosoda H, Kishida S, Kangawa K, Sakurai T, and Uezono Y. (2017):** Therapeutic potential of ghrelin and des-acyl ghrelin against chemotherapy-induced cardiotoxicity. *Endocrinology J*; 64(Suppl.): S35-S39.
- 32) **Oliveira Filho LD, Saad KR, Saad PF, Koike MK, Silva SM, and Montero EF. (2015):** Effect of N-acetylcysteine in hearts of rats submitted to controlled hemorrhagic shock. *Rev Bras Cir Cardiovasc*; 30 (2):173-181.
- 33) **Olorundare O, Adeneye A, Akinsola A, Kolo P, Agede O, Soyemi S, Mgbehoma A, Okoye I, Albrecht R, and Mukhtar H. (2020):** Irvingia gabonensis Seed Extract: An Effective Attenuator of Doxorubicin-Mediated Cardiotoxicity in Wistar Rats. *Oxid Med Cell Longev* 22;1602816.
- 34) **Pereira J E. G, El Dib R, Braz L G, Escudero J, Hayes J, and Johnston B C. (2019).** N-acetylcysteine use among patients undergoing cardiac surgery: A systematic review and meta-analysis of randomized trials. *PloS one*, 14(5), e0213862.
- 35) **Rashid S, Ali N, Nafees S, Ahmad ST, Arjumand W, Hasan SK, and Sultana S. (2013):** Alleviation of Doxorubicin- induced nephrotoxicity and hepatotoxicity by chrysin in Wistar rats. *Toxicology. Mech. Methods*; 23:337– 345
- 36) **Reddy PS, Rani GP, Sainath SB, Meena R, and Supriya C. (2011):** Protective effects of N-acetylcysteine against arsenic-induced oxidative stress and reprotoxicity in male mice. *Journal of Trace Elements in Medicine and Biology* 25: 247-253.
- 37) **Rehman MU, Tahir M, Khan AQ, Khan R, Oday-O-Hamiza, Lateef A, Hassan SK, Rashid S, Ali N, Zeeshan M, and Sultana S. (2014):** D-limonene suppresses doxorubicin-induced oxidative stress and inflammation via repression of COX-2, iNOS, and NFκB in kidneys of Wistar rats. *Experimental Biology and Medicine* (Maywood); 239(4):465-476.
- 38) **Saad SY, Najjar TA, and Alashari M. (2004):** Cardiotoxicity of doxorubicin/paclitaxel combination in rats: effect of sequence and timing of administration. *Journal of Biochemical Molecular Toxicology*; 18 (2):78-86.
- 39) **Samuni Y, Goldstein S, Dean OM, and Berk M. (2013):** The chemistry and biological activities of N-acetylcysteine. *Biochimica Biophysica Acta*; 1830(8):4117- 4129.
- 40) **Sathish P, Paramasivan V, Palani V, and Sivanesan K. (2011):** N- acetylcysteine attenuates dimethylnitrosamine induced oxidative stress in rats. *European Journal of Pharmacology*;

654(2):181-186.

41) **Shi R, Huang CC, Aronstam RS, Ercal N, Martin A, and Huang YW. (2009):** N-acetylcysteine amide decreases oxidative stress but not cell death induced by doxorubicin in H9c2 cardiomyocytes. *BMC Pharmacology*; 9(1): 1-9.

42) **Shivakumar P, Rani MU, Reddy AG, and Anjaneyulu Y. (2012):** A study on the toxic effects of Doxorubicin on the histology of certain organs. *Toxicol Int*; 19(3):241-244.

43) **Swamy AV, Gulliaya S, Thippeswamy A, Koti BC, and Manjula DV. (2012):** Cardioprotective effect of curcumin against doxorubicin-induced myocardial toxicity in albino rats. *Indian Journal of Pharmacology*; 44(1):73-77.

44) **Teodorczyk M, and Schmidt MH. (2014):** Notching on Cancer's door: notch signaling in brain tumors. *Front Oncology*; 4:341.

45) **Villani F, Galimberti M, Monti E, Piccinini F, Lanza E, Rozza A, Favalli L, Poggi P, and Zunino F. (1990):** Effect of glutathione and N-acetylcysteine on in vitro and in vivo cardiac toxicity of doxorubicin. *Free Radical Research Communication*; 11(1-3):145-151.

46) **Walaa I. Mohammed, Rania A. Radwan, and Hoda M. Elsayed. (2019):** "Prophylactic and Ameliorative Effect of N-Acetylcysteine on Doxorubicin-Induced Neurotoxicity in Wister Rats," *Egyptian Journal of Basic and Clinical Pharmacology*, Vol. 9, Article ID 101396, 16 pages,

doi:10.32527/2019/ 101396

47) **Wali AF, Rashid S, and Rashid SM. (2020):** Naringenin Regulates Doxorubicin-Induced Liver Dysfunction: Impact on Oxidative Stress and Inflammation. *Plants (Basel)*; 9(4):550.

48) **Wang T, Qiao S, and Lei S. (2011):** N-acetylcysteine and allopurinol synergistically enhance cardiac adiponectin content and reduce myocardial reperfusion injury in diabetic rats. *PLoS One*; 6(8):e23967.

49) **Wenningmann N, Knapp M, Ande A, Vaidya TR, and Ait-Oudhia S. (2019):** Insights into Doxorubicin-induced Cardiotoxicity: Molecular Mechanisms, Preventive Strategies, and Early Monitoring. *Molecular Pharmacology*; 96(2):219- 232.

50) **Yu J, Wang C, Kong Q, Wu X, Lu JJ, and Chen X. (2018):** Recent progress in doxorubicin-induced cardiotoxicity and protective potential of natural products. *Phytomedicine*; 40:125-139.

51) **Zafarullah M, Li WQ, Sylvester J, and Ahmad M. (2003):** Molecular mechanisms of N-acetylcysteine actions. *Cell Molecular Life Science GMLS*; 60(1):6-20.

52) **Zhan S, Fan X, Zhang F, Wang Y, and Kang L. (2015):** A proteomic study of Shengmai injection's mechanism on preventing cardiac ischemia-reperfusion injury via energy metabolism modulation. *Molecular BioSystems* 11(540 – 548).

الملخص العربي

دور مادة إن أسيتيل سيستايين في الوقاية من سمية عقار دوكسوروبيسين على أنسجة القلب للفئران

عماد الدين محمد الطاهر محمد محمود¹ رندة حسين عبد الهادي² صفاء ماهر جورج² عبير الرفاعي محمد الرفاعي³ رانيا أحمد رضوان⁴
¹قسم الطب الشرعي و السموم الإكلينيكية - كلية الطب - جامعة أسوان - مصر ²قسم الطب الشرعي و السموم الإكلينيكية - كلية الطب - جامعة
 أسيوط - مصر ³ قسم الباثولوجيا - كلية الطب - جامعة أسيوط مصر ⁴ قسم الطب الشرعي و السموم الإكلينيكية - كلية الطب - جامعة سوهاج -
 مصر .

مقدمة البحث يعتبر دواء دوكسوروبيسين من أهم مضادات السرطان التي تستخدم في علاج العديد من الأورام ولكن الاستخدام طويل المدى له غالباً ما يكون محدوداً نظراً لما يسببه من سمية القلب وكذلك العديد من أجهزة الجسم الأخرى. **الهدف من البحث** هو الاستدلال والتعرف على التأثير الوقائي المحتمل لعلاج إن أسيتيل سيستايين وذلك بجرعات مختلفة في الاعتلال والسمية المحدثة بعقار دوكسوروبيسين في الفئران . **طريقة البحث** أجريت هذه الدراسة على عدد (60) فأراً من ذكور الفئران البيضاء البالغة مقسمة إلى (6) مجموعات (10) فئران في كل مجموعة. المجموعة الأولى: المجموعة الضابطة. المجموعة الثانية: تم إعطاؤها محلول إن أسيتيل سيستايين عن طريق أنبوب بالفم بجرعة (400) مجم لكل كجم يوم بعد يوم. المجموعة الثالثة: تم حقن الفئران بجرعة واحدة من دوكسوروبيسين (5) مجم لكل كجم مرة واحدة أسبوعياً لمدة أربعة أسابيع. المجموعة الرابعة: تم البدء بإعطاء جرعات إن أسيتيل سيستايين بالفم بجرعة (400) مجم لكل كجم يوم بعد يوم لمدة أسبوع ثم من الأسبوع الثاني تم حقنها بعقار دوكسوروبيسين داخل الغشاء البروتوني بجرعة (5) مجم لكل كجم من وزن الجسم أسبوعياً لمدة أربعة أسابيع بالتزامن مع إعطاء مادة إن أسيتيل سيستايين لنهاية مدة الدراسة. المجموعة الخامسة: تم حقنها بعقار دوكسوروبيسين بجرعة (5) مجم لكل كجم من وزن الجسم بالتزامن مع جرعات إن أسيتيل سيستايين بالفم بجرعة (400) مجم لكل كجم من وزن الجسم يوم بعد يوم لمدة أربعة أسابيع. المجموعة السادسة: تم حقنها بعقار دوكسوروبيسين بجرعة (5) مجم لكل كجم من وزن الجسم أيام بالتزامن مع جرعات إن أسيتيل سيستايين بالفم بجرعة (800) مجم لكل كجم يوم بعد يوم لمدة أربعة أسابيع. **النتائج** تسبب عقار إن أسيتيل سيستايين في وجود فرق ذو دلالة إحصائية عند فحص أنسجة القلب ما بين عينات المجموعة الثالثة وباقي المجموعات في الوقاية من التغيرات المحدثة بواسطة عقار دوكسوروبيسين المتمثل في نقص إنزيمات القلب ونقص في عوامل الضغوط الأكسديدية وهي خفض الدهون فائقة التأكسد مع زيادة ملحوظة في الجلوتاثيون وانزيم بيروكسيدات الجلوتاثيون وكذلك وجود فرق ليس ذو دلالة إحصائية بين المجموعة الرابعة والتي تمثل إعطاء العقار قبل عقار دوكسوروبيسين بأسبوع والخامسة والسادسة التي تم إعطاء العقاران بالتزامن مع بعضهما في نفس الوقت. ووجود فرق ذو دلالة إحصائية لبعض العوامل في المجموعة السادسة عن الرابعة والخامسة. وقد أظهر التحليل الباثولوجي إستعادة معظم الشكل و التركيب الطبيعي لعضلة القلب مع عدم وجود أي دلائل باثولوجية بألياف عضلة القلب للمجموعة السادسة. **الخلاصة:** لم يتسبب عقار إن أسيتيل سيستايين بحدوث آثار سمية معينة في أنسجة القلب و لم يتبين أفضلية أي من الجرعتين عن الأخرى (400و 800مجم) التي تم إعطاءهم بالتزامن مع عقار دوكسوروبيسين. **التوصيات** يمكن استخدام عقار إن أسيتيل سيستايين للوقاية من الآثار السمية الناجمة عن عقار دوكسوروبيسين أثناء إستخدامه لعلاج بعض الأورام وتكون هذه الوقاية ناتجة عن خفض تكوين الدهون فائقة التأكسد واستعادة حالة منع التأكسد الانزيمية وغير الإنزيمية. يجب إجراء دراسات أخرى على استخدام عقار إن أسيتيل سيستايين في الوقاية من سمية عقار دوكسوروبيسين وذلك بإستخدام جرعات مختلفة ولمدة زمنية مختلفة وقياس كفاءة هذه الوقاية و كذلك في الوقاية من سمية أدوية علاج السرطانات الأخرى.